

Papillary Carcinoma of Thyroglossal Duct Cyst with a Normal Thyroid Gland Appearance: A Case Report

Wan Ahmad Amiruddin Wan Hassan^{1,2}, Khairul Azhar M. Rajet¹, Mohd Najeb Md Soleh¹, Wan Ishlah Leman²

1 Department of Otorhinolaryngology-Head and Neck Surgery, Hospital Tengku Ampuan Afzan, Kuantan, Pahang, Malaysia

2 Department of Otorhinolaryngology-Head and Neck Surgery, Sultan Ahmad Shah Medical Centre @IIUM, Kuantan, Malaysia

Received

3rd June 2021

Received in final revised form

2nd November 2021

Accepted

3rd January 2022

Published

1st March 2024

Corresponding author:

Dr Wan Ahmad Amiruddin Wan Hassan,

MBBS (IIUM), Master of Surgery (ORL-HNS IIUM), Hospital Tengku Ampuan Afzan Kuantan, Sultan Ahmad Shah Medical Centre @IIUM, Kuantan, Pahang, Malaysia.
Email: amiruddin1988@gmail.com

ABSTRACT

Thyroglossal duct cysts (TGDC) are the most common cause of midline anterior neck mass and are mostly located below the hyoid bone. The gold standard of treatment is the Sistrunk's operation in which the cyst along with the entire tract and part of the hyoid bone is excised to prevent any remnants and recurrence. Malignant changes in thyroglossal duct cyst are very rare and contributed to about 1-3.2%. Even though the incidence of TGDC carcinoma is rare but it should be one of the differential diagnoses of midline anterior neck mass. Papillary carcinoma of TGDC accounted for about 75-80% of all types of TGDC carcinoma. Papillary carcinoma of TGDC is diagnosed postoperatively following excision of the cyst itself. Due to the rarity of TGDC carcinoma, there is a controversy regarding the need for total thyroidectomy in the management of TGDC malignancy.

KEYWORDS: Thyroglossal duct cyst, thyroglossal duct cyst carcinoma, Sistrunk's operation, thyroidectomy

INTRODUCTION

Thyroglossal duct cysts (TGDC) are the commonest form of congenital abnormality in the head and neck region. They account for about 70% of cases in children and 7% of cases in adults [1]. Thyroid glands develop from the foramen caecum and are situated between the anterior two-thirds and posterior one-third of the tongue. In the 3rd week of gestation, it will descend to the anterior part of the neck with intimate relation with the hyoid bone. Thyroglossal duct cyst are cysts which are remnants of the thyroglossal tract and are present as a central neck mass at the thyrohyoid membrane level. The most common site for TGDC is below the hyoid bone which contributes to about 65% of the cases [2]. Ultimately, the duct will degenerate and involute between the 7th and 10th weeks of gestation.

Nevertheless, in a smaller group of individuals, the thyroglossal duct does not undergo complete degeneration which is about 7% of the cases [3,4]. As a result, persistent remnants of the thyroglossal duct may be observed anywhere along the tract at the anterior part of the neck which contains thyroid tissues [5]. TGDC may undergo malignant changes; but this is extremely rare, occurring only in approximately 1-3.2 % of cases [5-9].

To date, whether the TGDC carcinoma is derived from thyroid gland malignancy itself or a primary papillary carcinoma within the thyroglossal duct cyst still remains a controversy [10-12]. Thus, we discuss the management of thyroglossal duct cyst carcinoma with a normal thyroid gland appearance.



CASE PRESENTATION

A 41-year-old lady presented at our centre with a complaint of rapidly enlarging painless midline anterior neck mass for 1 month associated with mild dysphagia and odynophagia. There was no hoarseness. She denied any history of surgery, trauma, or radiation exposure to the neck. She does not smoke or consume alcohol. There were no compressive symptoms and no hyper or hypothyroid symptoms.

General examination showed no audible stridor at rest. Neck examination showed a single midline anterior neck mass of 5 cm x 6 cm in dimension below the level of the hyoid bone. It moved upward with deglutition as well as tongue protrusion. It was non-tender, lobulated, hard in consistency, mobile in all directions with normal overlying skin. The thyroid gland and neck nodes were not palpable. There was no bruit presence. Other systemic examinations were

unremarkable. Endoscopic examinations of the pharynx and larynx revealed no significant findings.

Serum T4, thyroid-stimulating hormone (TSH), and other laboratory tests were within normal limits. Fine needle aspiration cytology (FNAC) showed few atypical cells.

A computed tomography (CT scan) of the neck (Figure 2) displayed huge multiseptated cystic mass measuring 4.4cm (W) x 3.3cm (W) x 4.1cm (CC) with an enhancing solid component within measuring 1.0 cm x 0.9 cm and located inferior to the hyoid bone. Laterally the mass was near to the left sternocleidomastoid muscle. Inferiorly it is minimally compressing the adjacent left upper thyroid lobe with an irregular margin with no clear demarcation seen between the mass and the adjacent strap muscles. No extension is seen into the larynx. Cervical lymph nodes are not enlarged, and submandibular and thyroid glands are normal.

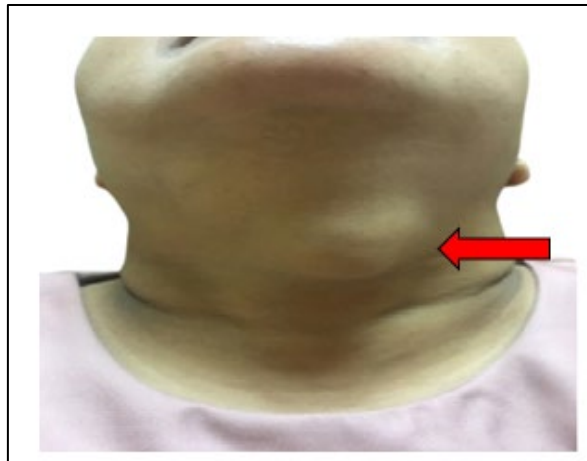

Figure 1 Midline anterior neck mass

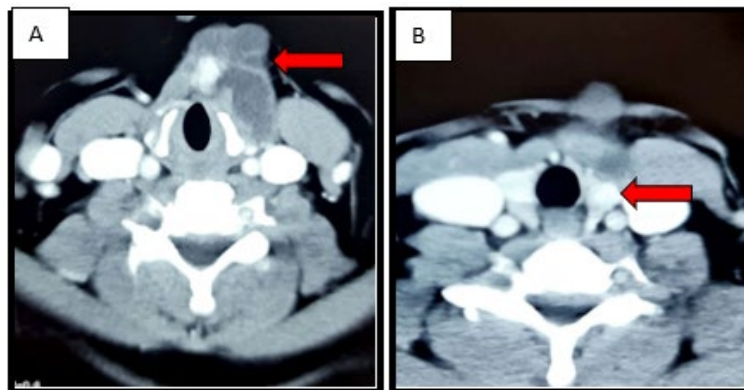


Figure 2 Axial section Ct scan of neck (A: showed complex cystic mass at anterior neck (slightly more on left side), B: Normal thyroid gland).

The patient underwent Sistrunk's operation under general anaesthesia in which a complete resection of the thyroglossal duct cyst and tract as well as the body of the hyoid bone were performed. There was a multilobulated cyst seated at the body of the hyoid bone. The tract was extending upward towards the base of the tongue. The complete specimen measured 4.5cm x 3cm x 3cm was sent for biopsy (Figure 3). The postoperative period was uneventful, and she was discharged home well.

Histopathological examination of the specimen showed presence of psammoma bodies, with no lympho-vascular invasion to the capsule and it was reported as papillary thyroid carcinoma. Three months post operatively, ultrasound guided FNAC of the thyroid gland was performed. It showed a benign follicular nodule suggestive of colloid goitre. The patient has been on regular 6 monthly follow-ups and has not shown any evidence of recurrence.

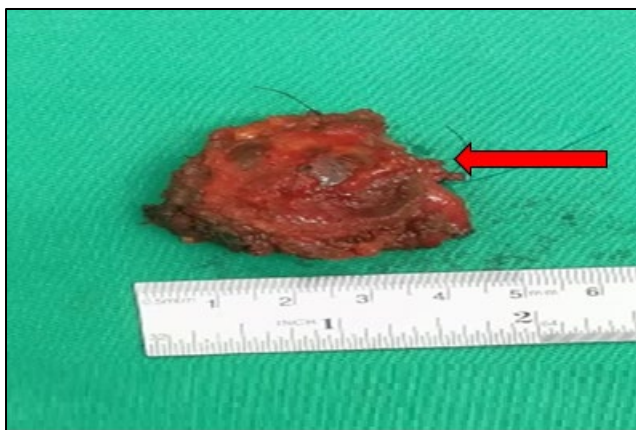

Figure 3 Thyroglossal duct cyst specimen removed by Sistrunk's operation

DISCUSSION

Thyroglossal duct cyst carcinoma more often affected women than men with a ratio of 3:1 [5]. The majority of TGDC carcinoma involves third and fourth decades of life and hardly occurs in children less than 14 years of age [10].

This is consistent with the patient who is a 41-year-old lady that presented with an anterior neck mass below the hyoid bone. The initial diagnosis of this patient was TGDC with the differential of TGDC carcinoma in view of a rapidly growing mass within a 1-month duration which is hard in consistency during

palpation. However, the patient denied any constitutional symptoms or history of radiation. In addition, FNAC of the mass showed cystic lesions with few atypical cells. Furthermore, CT scan neck revealed a complex cystic mass with the possibility of TGDC malignancy.

The most common types of TGDC carcinoma are papillary carcinoma which contributed about 75-80% of the cases followed by mixed papillary-follicular carcinoma (7%), squamous cell carcinoma (5%), follicular carcinoma (1.7%), anaplastic carcinoma, and Hurtle cell carcinoma (0.9%) [13]. In our case, the specimen was sent for histopathological examination and was revealed to be papillary carcinoma which corresponded with the past literatures.

There was a study by Tristan et al. [14], indicating that only 1.4% of papillary carcinoma of TGDC are presented in thyroglossal duct cyst (4 out of 282 cases). Three out of four patients underwent total thyroidectomy. However, none of them showed secondary carcinoma in the thyroid gland indicating that thyroidectomy was unjustifiably performed.

The best management of TGDC carcinoma is still debatable. It is suggested that in low-risk patients, the Sistrunk's operation is adequate for clinically and radiologically normal thyroid glands [4,15].

Those who are less than 45 years old, tumour size of < 4 cm, no prior radiation exposure, no soft tissue invasion, no distant or lymphatic metastasis, and no aggressive tumour histology are considered as low risk [4,15]. Radioactive iodine ablation (RAI) and total thyroidectomy are performed in high-risk patients as well as in cases with positive surgical margins [15]. Our patient is 41 years old with mass size of more than 4 cm. However, there is no history of radiation exposure, no soft tissue invasion, and no palpable cervical lymph nodes. Thus, total thyroidectomy is not indicated for this patient as ultrasound guided FNAC showed no evidence of malignancy.

CONCLUSION

Thyroglossal duct cyst carcinoma is a very rare finding in TGDC. It is diagnosed histopathologically following excision of the TGDC. The best method of treatment for TGDC carcinoma is still debatable until now.

Many studies suggested Sistrunk's operation alone for low-risk groups while total thyroidectomy plus radioactive iodine ablation (RAI) post operatively for high-risk groups. Nevertheless, further studies are needed for the best treatment of TGDC carcinoma.

Acknowledgment

We would like to thank all personnel who were involved in managing this case.

Conflict of Interest

Authors declare none.

Authors' contribution

Drafting the manuscript: WAA

Data collection: WAA

Data analysis: WAA, MNS, KA, WI

Final approval: KA, WI

REFERENCES

- Balalaa N, Megahed M, Ashari MAI, Branicki F. Thyroglossal duct cyst papillary carcinoma. *Case Rep Oncol*. 2011; 4(1): 39–43
- Nakayama S, Kimachi K, Nakayama K, Ikebe T, Ozeki S. Thyroglossal duct cyst occurring in the floor of the mouth: report of 2 cases. *J Oral Maxillofac Surg*. 2009; 67: 2690–269
- Jang DW, Sikora AG, Leytin A. Thyroglossal duct cyst carcinoma: case report and review of the literature. *ENT: Ear, Nose & Throat Journal*. 2013;92(9): E12–E14.
- Akram R, Wiltshire JJ, Wadsley J, Balasubramanian SP. Adult thyroglossal duct carcinoma of thyroid epithelial origin: a retrospective observational study. *Indian Journal of Otolaryngology and Head & Neck Surgery*. 2016; 68: 522-7.
- Thompson LD, Herrera HB, Lau SK. A Clinicopathologic Series of 685 Thyroglossal Duct Remnant Cysts. *Head Neck Pathol*. 2016; 10(4): 465-474. doi: 10.1007/s12105-016-0724-7.
- Maziak D, Borowy ZJ, Deitel M, Jaksic T, Ralph-Edwards A. Management of papillary carcinoma arising in thyroglossal-duct anlage. *Can J Surg*. 1992; 35: 522-525.
- Kennedy TL, Whitaker M, Wadiah G. Thyroglossal duct carcinoma: a rational approach to management. *Laryngoscope*. 1998; 108: 1154-1158.
- Miccoli P, Minuto MN, Galleri D, et al. Extent of surgery in thyroglossal duct carcinoma: reflections on a series of eighteen cases. *Thyroid* 2004; 14: 121-3.
- Moorthy SN, Arcot R. Thyroglossal duct cyst—more than just an embryological remnant. *Indian J Surg*. 2011; 73(1): 28–31.
- Gupta N, Dass A, Bhutani M, et al. Papillary carcinoma in thyroglossal duct cyst: An unusual case. *Egypt J Ear Nose Throat Allied Sci*. 2014; 15: 45–7.
- Baglam T, Binnetoglu A, Yumusakhuylu AC, Demir B, Askan G, Sari M. Does papillary carcinoma of thyroglossal duct cyst develop de novo?. *Case Reports in Otolaryngology*. 2015. Article ID 382760, 5 pages.
- Hilger AW, Thompson SD, Smallman LA, Watkinson JC. Papillary carcinoma arising in a thyroglossal duct cyst: a case report and literature review. *The Journal of Laryngology & Otology*. 1995; 109(11): 1124-7.
- Alatsakis M, Drogouti M, Tsompanidou C, Katsourakis A, Chatzis I. Invasive thyroglossal duct cyst papillary carcinoma: a case report and review of the literature. *The American Journal of Case Reports*. 2018; 19: 757-762.
- de Tristan J, Zenk J, Künzel J, Psychogios G, Iro H. Thyroglossal duct cysts: 20 years' experience (1992–2011). *European archives of oto-rhino-laryngology*. 2015; 272: 2513-9.
- Bakkar S, Biricotti M, Stefanini G, Ambrosini CE, Materazzi G, Miccoli P. The extent of surgery in thyroglossal cyst carcinoma. *Langenbeck's archives of surgery*. 2017; 402: 799-804.