

# **Lost in Space - Caldwell Luc Antrostomy for Retrieving Displaced Root into Maxillary Sinus: A Case Report**

**Sara Luay Thanoon<sup>1</sup>, Mohd Shawal Firdaus Mohamad<sup>1</sup>, Luay Thanoon Younis<sup>1\*</sup>**

<sup>1</sup>*Faculty of Dentistry, Universiti Teknologi MARA Sungai Buloh Campus, Jalan Hospital, 47000 Sungai Buloh, Selangor, Malaysia.*

\*Corresponding Author:

drluay@uitm.edu.my

Tel: 016-3811048

Received: February 02, 2023

Reviewed: April 01, 2023

Accepted for publication: June 20, 2023

## **ABSTRACT**

*The palatal root of the first permanent molar is the most commonly deflected root into the maxillary sinus during extraction. A rational approach to the surgical removal of a root from the antrum is important. Some surgeons prefer the alveolar approach while others prefer the Caldwell-Luc operation. In this report, a case was presented where the palatal root tip of the right upper first molar was displaced into the right maxillary sinus during simple extraction of the tooth which was later successfully removed from the maxillary sinus by the Caldwell-Luc approach. CBCT was used to locate and remove the lost root tip.*

**Keywords:** *Displaced root, maxillary sinus, Caldwell Luc antrostomy.*

## **INTRODUCTION**

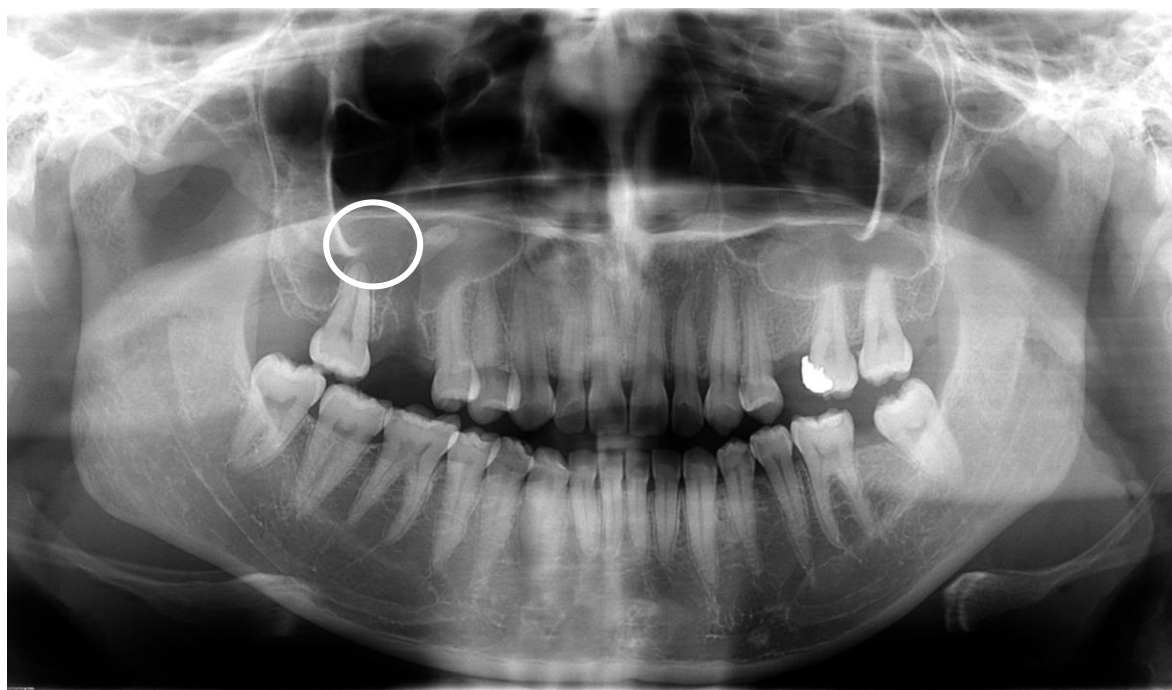
The Caldwell-Luc operation or radical antrostomy is used by oral and maxillofacial surgeons as an approach to the maxillary sinus for removal of roots of tooth, or antral foreign bodies, the otolaryngologists to treat chronic maxillary sinusitis, and head and neck surgeons in their surgical armamentarium for pterygomaxillary space surgery or decompression of Grave's ophthalmopathy (Huang et al., 2012; Datta et al., 2016). In dental procedures, it is not uncommon for the root apices of the upper first molar to be displaced into the sinus as they lie in close proximity to the antral floor. It had been shown that the extraction of the maxillary first molar root appeared to be forced into the antrum more often than the roots of other teeth (Toledano et al., 2021). These roots were displaced into the maxillary sinus more frequently in males than females and using radiographs to identify the root fragment (Huang et al., 2011). Although small fragments may remain asymptomatic, removal is recommended, as even after long asymptomatic periods, complications such as oroantral fistulas, mucocelles, cellulitis or, more commonly, maxillary sinusitis, which can affect 48% to 73% of patients, may arise (Hara et

al., 2018). This case report aims to describe the use of CLM technique to remove a dental fragment accidentally displaced into the maxillary sinus, during the extraction of maxillary molars.

## CASE REPORT

A 31-year-old medically fit female patient was referred to the UiTM Dental Centre (Oral and Maxillofacial Surgery department) from a private clinic due to the displacement of palatal root of the maxillary right first molar into the right maxillary sinus in an attempt to extract the mentioned tooth due to unrestorable tooth decay. The dentist who referred the case claimed that during the process of luxation, the palatal root of the tooth was dislodged into the right maxillary sinus and the attempt to retrieve the palatal root failed.

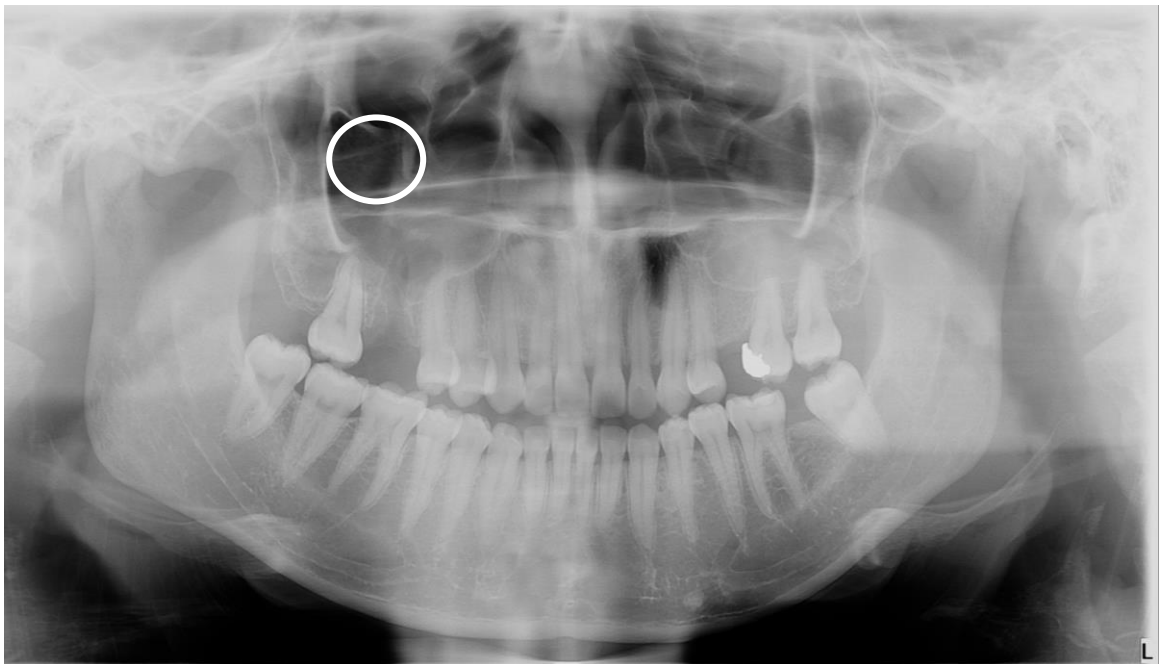Extraoral examinations show no abnormalities. Intra oral examination on the site of complaint shows a non-healing extraction socket with oroantral fistula. At first, the palatal root of upper right first molar was difficult to be localised. A panoramic radiography of the maxillaries was requested for complementary diagnosis. OPG showed a well-defined socket wall of the extracted upper right first molar and a well-defined conical radiopaque object floating in the right maxillary sinus and above the extraction site of tooth indicated the location of the displaced palatal root (**Fig. 1**). The treatment proposed by the OMFS team was Caldwell-Luc access antrostomy to retrieve the displaced palatal root.



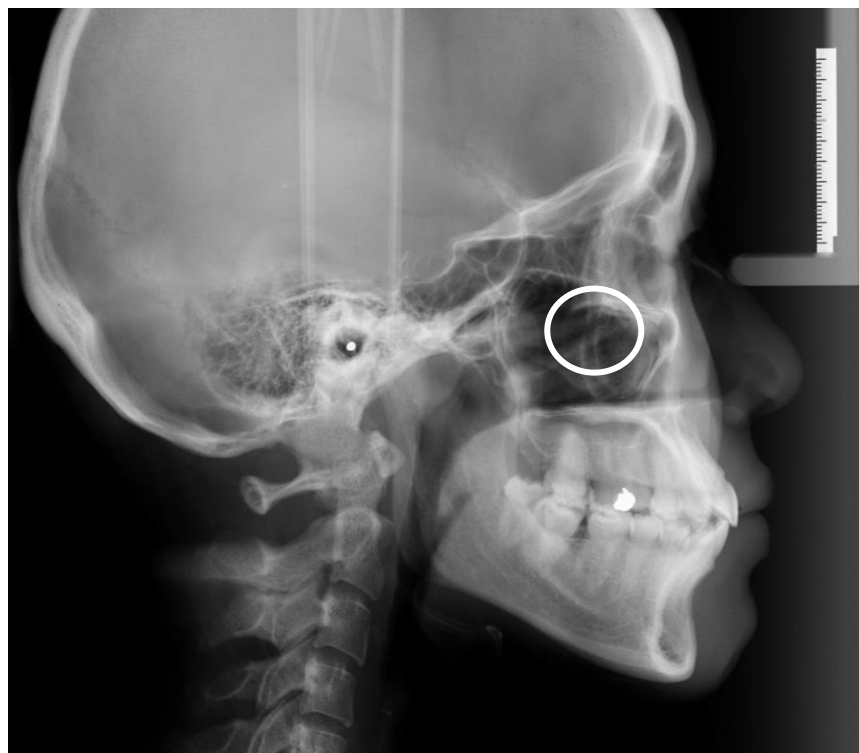**Figure 1: an orthopantomogram shows displaced palatal root of 16 into the right maxillary sinus**

A written consent was taken from the patient. The surgical procedure started with aseptic technique with washing the operating field by chlorhexidine. This is followed with infiltration of 2% lidocaine + epinephrine 1:200000 at the back of the right-side maxillary vestibule. Then two releasing incisions in the buccal alveolar mucosa that end on the mucogingival line were done. Afterwards, mucoperiosteal detachment, bone exposure, and Caldwell-Luc antrostomy with a spherical drill #8 to access the maxillary sinus were made. The maxillary membrane was removed and the access was used for continuous irrigation with normal saline followed by suction of the sinus fluids in an attempt to retrieve the palatal root tip with the surgical suction. After repeated attempts of irrigation and suction, retrieval of the root tip was failed. At that time, displacement of the root tip from its original position was suspected. An orthopantomogram (**Fig. 2A**), lateral cephalogram (**Fig. 2B**), and cone beam computed tomography were implemented for further investigation (**figure 2C**). Diagnostic imaging all showed displacement of the palatal root tip further to the superior area of maxillary sinus. Once the

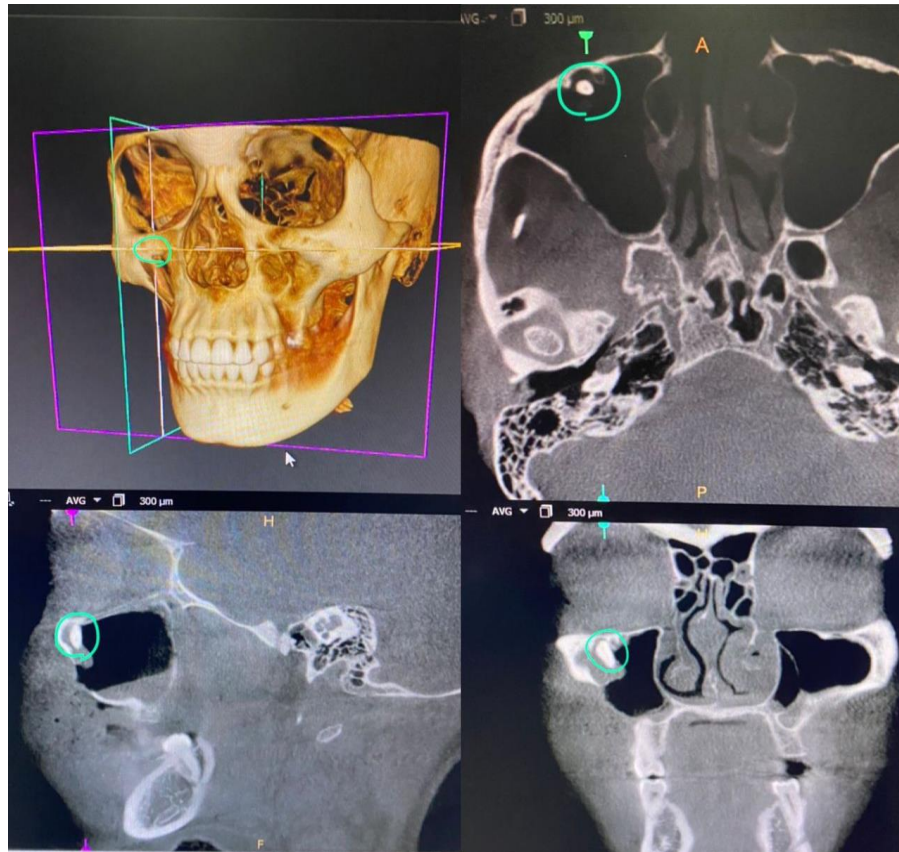
location of the root tip was determined, the final attempt to retrieve the root tip was successful using the surgical suction tip. (**Fig. 3**).



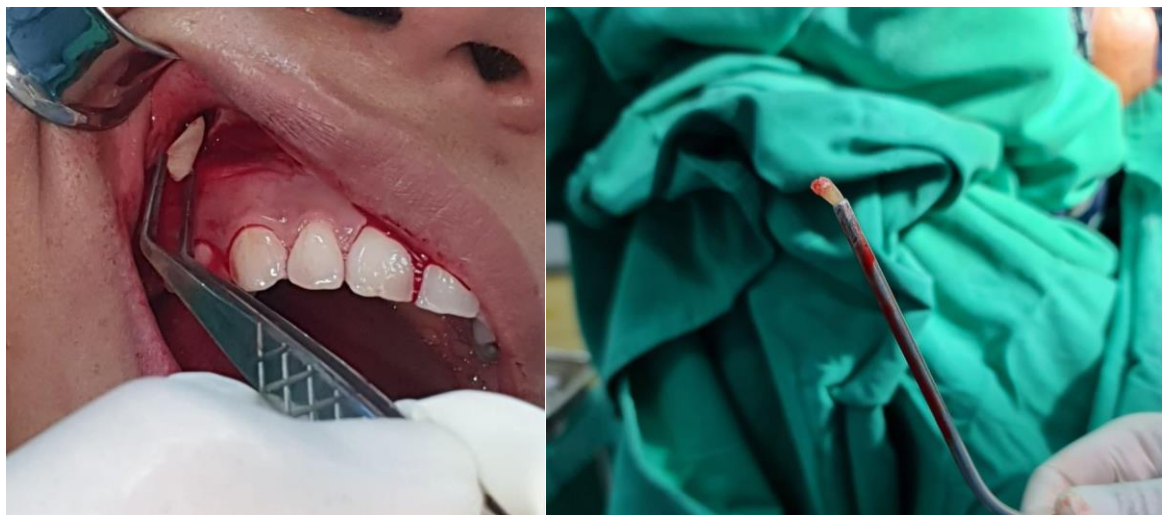
**Figure 2a: Diagnostic imaging showed displacement of the root tip of upper right molar to the superior area of maxillary sinus.**



**Figure 2b: Lateral Cephalogram**



**Figure 2C: Cone beam computed tomography shows displacement of the palatal root tip of upper right molar the superior area maxillary sinus**



**Figure 3: Successful retrieval of palatal root from the right maxillary sinus**

Afterwards, the flap suturing was done using 3.0 Vicryl suture and lock stitch suture technique was implemented. Haemostasis was achieved and post-surgical instructions were given. Antibiotic and analgesics were prescribed as followed: Amoxicillin + Clavulanic Acid, Tab 625 mg TDS/7 days; and Metronidazole, Tab TDS/7days 400mg; Etoricoxib (Arcoxia), Tab 90 mg QD/3 days , Paracetamol Tab 500 mg QD/3 days.

The patient was reviewed after 7 days, and the healing was uneventful with no signs of oroantral communication.



## DISCUSSION

Teeth or dental fragments can be displaced into the maxillary sinus during extractions, among the reasons for this incident are inappropriate use of instruments, improper choice of technique or inexperience of the surgeon. The presence of foreign bodies may result in chronic maxillary sinusitis, purulent exudate, oedema, facial asymmetry, localised pain and headache, and severe conditions such as cellulitis. Once foreign bodies have been moved into the sinus, these events should be addressed early to avoid severe complications. Evaluation of imaging exams, especially CT, is essential for a precise diagnosis and choice of proper surgical approach (Sencimen et al., 2017). Caldwell-Luc antrostomy was performed on our patient to retrieve displaced root into the maxillary sinus as it provides a direct view of the maxillary sinus and allows instrumentation, irrigation and removal of large objects, making it the treatment of choice for surgery at the maxillary sinus (Sivolella et al., 2014).

A panoramic radiograph is the routine diagnostic radiographic examination performed, although cone beam computed tomography (CBCT) is highly recommended for further localization of the migrated root into the maxillary sinus and assessment of the characteristics of any associated lesion before a surgical procedure. CBCT presents an accurate three-dimensional imaging modality that offers highly diagnostic images with a sub-millimetre resolution, short scanning time and reduced radiation dose up to 15 times less than multi-slice CT scans (Scarfe et al., 2006). It was reported that better accuracy and significant interobserver agreement in the evaluation of ectopic tooth location when using CBCT as compared to panoramic radiograph (alqerban et al., 2011). In this case report, we highlighted the importance of the CBCT imaging in addition to other radiographic imaging modalities prior to attempting Caldwell Luc surgery for retrieval of displaced palatal root of upper right first molar into the maxillary sinus, to verify its precise location and to minimise the invasive surgery as OPG was not enough.

## CONCLUSION

The presence of foreign bodies inside the maxillary sinus can lead to a series of complications, the most common of which is maxillary sinusitis. The displacement of teeth or dental fragments into the sinus, although rare, may occur during extraction of maxillary molars; these incidents should be addressed as soon as possible. The CLM technique is a simple, fast, and effective way to retrieve dental fragments displaced into the maxillary sinuses, offering the possibility of being performed in an ambulatory facility under local anaesthesia, with minimal risk, low costs and low complication rates, when performed by dentists with good training in oral surgery. 3-dimensional imaging with a CBCT scan is considered as a gold standard because it can precisely locate the displaced tooth or root and detect any changes in the maxillary sinus (Alqerban et al., 2011; Botticelli, 2022).

## REFERENCES

- Alqerban A, Jacobs R, Fieuws S, Willems G. Comparison of two cone beam computed tomographic systems versus panoramic imaging for localization of impacted maxillary canines and detection of root resorption. *European journal of orthodontics*. 2011;33(1):93-102.
- Botticelli D. Clinical and Histological Healing after Maxillary Sinus Floor Elevation. *Dentistry Journal*. 2022;10(7):134.
- Datta RK, Viswanatha B, Shree Harsha M. Caldwell Luc Surgery: Revisited. *Indian J Otolaryngol Head Neck Surg*. 2016;68(1):90-3.
- Hara Y, Shiratsuchi H, Tamagawa T, Koshi R, Miya C, Nagasaki M, et al. A large-scale study of treatment methods for foreign bodies in the maxillary sinus. *J Oral Sci*. 2018;60(3):321-8.
- Huang IY, Chen CM, Chuang FH. Caldwell-Luc procedure for retrieval of displaced root in the maxillary sinus. *Oral Surg Oral Med Oral Pathol Oral Radiol Endod*. 2011;112(6):e59-63.

- Huang YC, Chen WH. Caldwell-Luc operation without inferior meatal antrostomy: a retrospective study of 50 cases. *J Oral Maxillofac Surg.* 2012;70(9):2080-4.
- Toledano-Serrabona J, Cascos-Romero J, Gay-Escoda C. Accidental dental displacement into the maxillary sinus during extraction maneuvers: a case series. *Med Oral Patol Oral Cir Bucal.* 2021;26(1):e102-e7.
- Scarfe WC, Farman AG, Sukovic P. Clinical applications of cone-beam computed tomography in dental practice. *J Can Dent Assoc.* 2006;72(1):75-80.
- Sencimen M, Gülses A, Secer S, Zerener T, Özarslantürk S. Delayed retrieval of a displaced maxillary third molar from infratemporal space via trans-sinusoidal approach: a case report and the review of the literature. *Oral Maxillofac Surg.* 2017;21(1):1-6.
- Sivolella S, Ricci S, Busca M, Stellini E, Valente M. Maxillary dentigerous cyst associated with an ectopic third molar in the maxillary sinus: a literature review and report of six consecutive cases. *Oral Surgery.* 2014;7(S1):72-8.