

Recurrent Stroke in a Young Man with Moyamoya Disease on Medical Therapy: A Case Report

Nurfauzani Ibrahim¹, Noorhida Baharudin¹, Hilwati Hashim², Thinesh Kumaran Jaya Raman³, Mohamed-Syarif Mohamed-Yassin¹

1 Department of Primary Care Medicine, Faculty of Medicine, Universiti Teknologi MARA, Selayang Campus, Selangor, Malaysia

2 Department of Radiology, Faculty of Medicine, Universiti Teknologi MARA, Sungai Buloh Campus, Selangor, Malaysia

3 Department of Neurosurgery, Hospital Kuala Lumpur, Ministry of Health, Malaysia

Received

10th February 2021

Received in revised form

1st March 2021

Accepted

30th April 2021

Corresponding author:

Dr. Noorhida Baharudin,

Department of Primary Care Medicine,

Faculty of Medicine,

Universiti Teknologi MARA (UiTM),

Selayang Campus,

Jalan Prima Selayang 7,

68100 Batu Caves, Selangor,

Malaysia.

Email: noorhida8229@uitm.edu.my

ABSTRACT

Moyamoya disease (MMD) is a rare intracranial vasculopathy characterized by the progressive occlusion of the terminal internal carotid arteries and their proximal branches. Various factors including genetic and inflammation are the proposed pathogenesis of MMD. We present a case of a 31-year-old man who had recurrent stroke secondary to MMD. Magnetic resonance imaging (MRI) and magnetic resonance angiography (MRA) demonstrated an infarct in the right middle cerebral artery (MCA) territory, and stenosis of the terminal right internal carotid artery (ICA) and its proximal branches. He initially declined surgical management and was treated with antiplatelet. After his third stroke, he finally underwent right superficial temporal artery (STA) to middle cerebral artery (MCA) bypass surgery. He improved following rehabilitation with no further recurrence. The role of surgical revascularization in the prevention of stroke is well-described in the literature but evidence regarding medical therapy remain scarce and will be explored in this report.

KEYWORDS: Moyamoya Disease, Stroke, Secondary Prevention

INTRODUCTION

Stroke remains a major health burden worldwide. Stroke in a young person can be devastating due to the loss of productive years and impact on the young person's life [1]. While there is no consensus on the definition of young stroke, many literature refer to the occurrence of stroke in an individual under 45 years of age [1]. Stroke in young people is due to different aetiologies compared to older patients, so a different approach is needed [1]. Arriving at a diagnosis and its underlying aetiology early is essential to ensure appropriate and timely intervention, and subsequently reduces the risk of recurrent stroke [2]. Moyamoya disease (MMD) is one of the causes of stroke among the young, characterized by the progressive stenosis of large intracranial arteries leading to ischemia of the basal ganglia [3]. Several studies have discussed the role of surgical revascularization in the prevention of

strokes among patients with MMD [2, 4]. In terms of medical treatment, antiplatelet agents have been used to prevent stroke in these patients [5]. Thus, this case report aims to discuss the role of antiplatelet treatment as well as other secondary prevention medications such as statin as part of the management for MMD.

CASE PRESENTATION

A 31-year-old man presented with sudden onset of left sided hemiparesis and facial asymmetry for one day prior to admission. He did not have any slurred speech, headache or blurring of vision. He was on aspirin 150mg OD, simvastatin 40mg ON and perindopril 4mg OD. His cardiovascular risk factors were hypertension and a 5-pack-year smoking history. There was no family history of hypertension, diabetes, cardiovascular disease, thrombosis or young stroke. On examination,



his body mass index (BMI) was 24 kg/m². His heart rate was 81 beats per minute with regular rhythm and blood pressure was 148/93 mmHg. Neurological examination of the left upper limb revealed power of 4+ /5 over the flexor muscles and 4- /5 over the extensor muscles. The power of the right upper limb and the lower limbs were normal. There were brisk reflexes over the left side of his body. There was also slight loss of left nasolabial fold, with no weakness of the facial muscles. Sensation was normal bilaterally.

This was his third stroke in five years, secondary to Moyamoya disease. His first stroke occurred at the age of 26 years old, when he developed left-sided body weakness and facial asymmetry. The work up for the causes of young stroke was performed during this episode. Blood investigations, which were full blood count, renal profile, liver function test, coagulation studies, thrombophilia and connective

tissue disease screening were all within normal ranges. Electrocardiogram, chest radiograph and transthoracic echocardiogram were also unremarkable. MRI and MRA showed acute right basal ganglia and external capsule infarct extending to the right corona radiata corresponding to the right MCA territory. On MRA, there were stenosis of the terminal right internal carotid artery (ICA) as well as the right middle cerebral artery (MCA) and anterior cerebral artery (ACA) (Figure 1). He was seen by a neurosurgeon, but he declined surgical intervention at that stage as he was worried about the possible complication of the surgery. He was managed conservatively with physical rehabilitation and optimization of his cardiovascular risk factors such as smoking cessation, as well as secondary prevention medications (aspirin 150mg OD, simvastatin 40mg ON and perindopril 4mg). He continued to improve with minimal residual weakness.

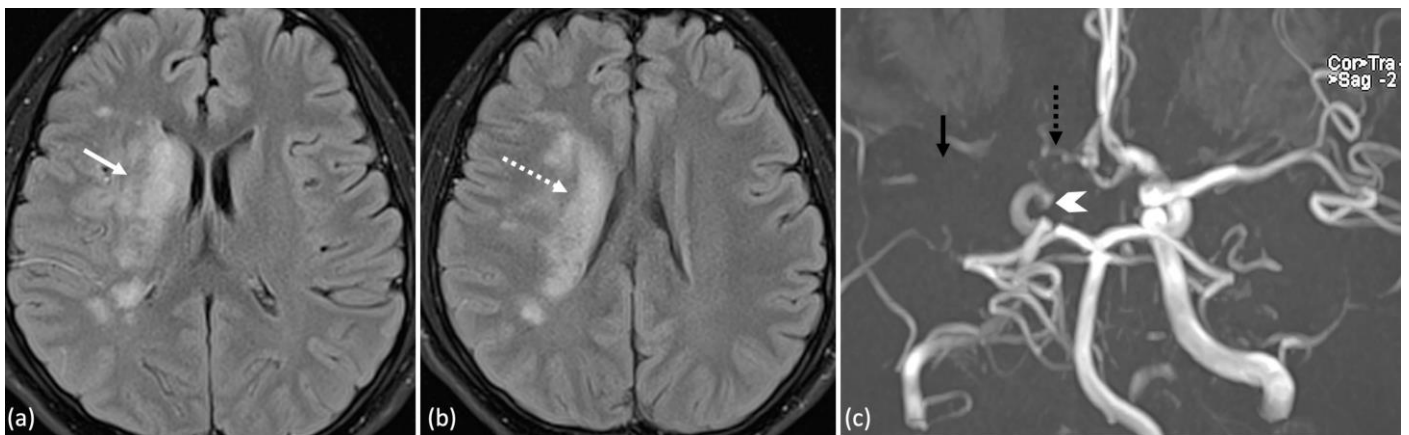


Figure 1 MRI and MRA images; (a) and (b) MRI Axial FLAIR sequence demonstrates acute infarct at the right basal ganglia and external capsule (white arrow) extending to the right corona radiata (dotted arrow). (c) MRA of the Circle of Willis demonstrates right intracranial stenosis at the terminal aspect of the right internal carotid artery (ICA) (white arrowhead). Note that the right middle cerebral artery (MCA) is not visualized here compared to the normal left side (black arrow), suggestive of right MCA stenosis. There is also stenosis of the A1 segment of right anterior cerebral artery (ACA) (black dotted arrow).

Following this event, he developed two further episodes of stroke. A repeat MRI showed the old right basal ganglia and corona radiata infarct as well as right ICA stenosis. This was further confirmed on CT angiogram (CTA). After three episodes of stroke within the span of five years, he finally agreed for surgical intervention. He underwent a superficial temporal artery (STA) to middle cerebral artery (MCA) bypass surgery.

He regained full neurological functions following regular rehabilitation sessions. During his follow up visit seven months after the surgery, his cardiovascular risk factors were optimized with a blood pressure of 125/80 mmHg, low-density lipoproteins (LDL) of 1.8 mmol/litre, high-density lipoproteins (HDL) of 1.2 mmol/ litre, total cholesterol of 3.5 mmol/ litre and fasting blood glucose of 5.1 mmol/ litre. He was able to quit smoking with support from his primary care doctors.

DISCUSSION

MMD is a rare intracranial vasculopathy with progressive stenosis of large intracranial arteries leading to ischaemia of the basal ganglia [3]. MMD was first described in the Japanese medical literature by Takeuchi and Shimizu in 1957 and then named MMD by Suzuki and Takaku in 1969 [3, 6]. The name 'moyamoya' means 'puff of smoke' in Japanese [3]. It describes the small abnormal cluster of collateral vessels that proliferates following distal ICA stenosis. MMD primarily affects Asians which accounts for 6%-15% of cases of non-atherosclerotic vasculopathy [7]. The disease affects children and young adults, but it can also occur in older adults. Genetic and inflammation have been suggested as possible aetiologies for MMD, although the exact mechanism is unknown [3]. A recent study suggested possible alteration in the RNF213 gene leading to the development as well as progression of MMD [3]. MMD causes ICA and MCA narrowing and ischaemia of the brain often follows [8]. The first symptom of MMD is often a stroke or recurrent transient ischaemic attacks (TIA) [9]. Other symptoms may include migraine-like headaches, seizures, disturbed consciousness, involuntary movements, visual problems, and cognitive or sensory impairment [9]. More than 60% of adult patients present with intracranial haemorrhage [10]. It is due to rupture of fragile deep collateral vessels with deep intraparenchymal (basal ganglia or periventricular deep white matter) or intraventricular haemorrhage [3].

MMD is diagnosed by visualization of distal stenosis of one or both internal carotid arteries and their branches which are the anterior cerebral artery and middle cerebral artery, as well as neovascularization which reflects the progressive nature of the disease [3]. CTA and MRA have been widely accepted for evaluation of MMD [11, 12]. These modalities may provide clues for preliminary diagnosis especially in those who have mild symptoms [11].

The aim of treatment of MMD is to prevent cerebral infarction by improving cerebral blood flow and restoring reserve capacity [2]. Treatments are categorized into medical and surgical methods. During the acute event, medical treatment is proposed to avoid further stroke [13]. These include control of fever, blood pressure and glucose level, as well as pain, and

seizure medication, if any occurs [13]. Antithrombotic medications, such as aspirin have also been proposed during the acute event albeit the insufficient evidence [13].

As for the long-term medical management, evidence regarding the role of secondary prevention medications for stroke among patients with MMD remains scarce. MMD is a form of non-atherosclerotic vasculopathy, therefore antiplatelet treatment is ineffective to avoid recurrent ischaemic cerebral infarction [2]. The nature of ischaemic insult in patients with MMD is haemodynamic infarction [2]. The pathological change of the vessels near the ICA bifurcation is not a form of endothelial damage that platelets are likely to bind to [2]. Although the evidence regarding the role of antiplatelet therapy for secondary prevention of stroke from MMD is lacking, its use was not associated with increased cerebral haemorrhage [14]. Nevertheless, the use of antiplatelet agents, as an alternative to surgical revascularization for symptomatic MMD patients should not yet be considered as an appropriate treatment choice [2].

The role of blood pressure control has been reported to prevent rebleeding after an acute haemorrhagic event in patients with MMD [10]. Strict blood pressure control is also advocated after bypass surgery in patients with MMD [11]. Following bypass, achieving target systolic blood pressure of 130 mmHg or less is important to prevent post-bypass hyperperfusion syndrome [11]. Literature regarding statins for secondary prevention of stroke among patients with MMD is lacking. Some medical conditions, including hyperlipidaemia and atherosclerosis have been found to commonly co-exist in patients with MMD [15]. The role of statin in atherosclerotic vasculopathy is clear [16]. Thus, its use is sensible among MMD patients who have hyperlipidaemia as a comorbidity. Zakarli et al. discovered that smokers have approximately four times increased likelihood of developing long term focal symptoms or radiological progression, compared to non-smokers [17]. Other studies also discovered similar findings where smoking has been shown to be a strong predictor for the recurrence of stroke, as well as radiological progression of MMD [18, 19]. Thus,

management of cardiovascular risk factors, especially smoking cessation is vital in managing MMD.

The mainstay treatment for MMD is revascularization [20]. Surgical revascularization is recommended for symptomatic patients with recurrent stroke [2], and those with recurrent haemorrhagic events [21]. Surgical techniques can be divided into direct, indirect or combination technique [2]. Direct surgical procedures immediately improve the cerebral blood flow [22]. This procedure includes superficial temporal artery to middle cerebral artery (STA-MCA) anastomosis, superficial temporal artery to anterior cerebral artery (STA-ACA) anastomosis and occipital artery to posterior cerebral artery (OA-PCA) anastomosis [13]. Another technique is indirect revascularization, which promotes the development of new vascular network over time [2].

Indirect surgical procedures include encephaloduro-arterio-synangiosis (EDAS), encephalomyosynangiosis (EMS), encephalo-duro-arterio-myosynangiosis (EDAMS) or multiple burr-hole operation [13]. The combined surgical procedures (direct and indirect) immediately augment cerebral blood flow, as well as promote improved perfusion over time [23]. Combined procedures have been shown to produce a more extensive area of angiographic revascularization, compared to direct and indirect technique [13]. Comparing direct and indirect technique, the Japanese Adult Moyamoya (JAM) trial proposed a direct bypass technique for its preventative effect against bleeding in haemorrhagic type of MMD [21]. However, Dong-Kyu et al. reported there were no significant differences for the recurrence of stroke, perioperative stroke, and mortality among those treated with direct, indirect or combined bypass [19]. A systematic review by Kazumata et al. also reported similar postoperative stroke rates between direct and indirect bypass groups [24]. While the evidence regarding the best surgical method remains controversial, direct bypass has been proposed to be safer and more efficacious, and may produce better revascularization from angiography, as well as a better outcome [22].

In terms of prognosis, Kuroda et al. reported a disease progression rate of approximately 20% over six years. In addition, progressive neurologic deficits and poor outcome were seen in 50% to 66% of untreated patients [25]. Comparing conservative management versus surgical revascularisation, the JAM trial discovered that patients with haemorrhagic MMD who were treated with direct bypass surgery developed less rebleeding rates and have improved prognosis [21]. Furthermore, among medically treated patients, the recurrence of strokes was 25%, versus 16.5% in the bypass group [19]. In terms of mortality reduction, several studies found that there was no significant difference between medical treatment and bypass surgery [19, 26]. The overall mortality rate from MMD is about 10% in adults and 4.3% in children [27].

CONCLUSION

Surgical intervention remains the mainstay therapy for MMD. The evidence regarding antiplatelet and other secondary prevention medications is lacking. However, their roles, specifically blood pressure control, have been proposed to prevent rebleeding in haemorrhagic MMD, as well as following bypass surgery. Statins have also been used in patients with hyperlipidaemia as a comorbidity. Further research is needed to confirm the roles of medical management in preventing future strokes among patients with MMD.

Conflict of Interest

Authors declare none.

Acknowledgements

The authors would like to thank the patient for his consent to allow us to share his story.

Authors' contribution

All authors were involved in the conception of this case report. Nurfauzani Ibrahim drafted the manuscript. All authors critically revised the manuscript for important intellectual content. All authors read and approved the final version submitted.

REFERENCES

1. Griffiths D, Sturm J. Epidemiology and etiology of young stroke. *Stroke research and treatment*. 2011. 209370-209370.
2. Kim T, Oh CW, Bang JS, Kim JE, Cho WS. Moyamoya Disease: Treatment and Outcomes. *Journal of stroke* 2016; 18(1): 21-30.
3. Guey S, Tournier-Lasserre E, Hervé D, Kossorotoff M. Moyamoya disease and syndromes: from genetics to clinical management. *The application of clinical genetics* 2015; 8: 49.
4. Kim T, Oh CW, Kwon OK, Hwang G, Kim JE, Kang HS, Cho WS, Bang JS. Stroke prevention by direct revascularization for patients with adult-onset moyamoya disease presenting with ischemia. *Journal of neurosurgery*. 2016;124(6):1788-93.
5. Kraemer M, Berlit P, Diesner F, Khan N. What is the expert's option on antiplatelet therapy in moyamoya disease? Results of a worldwide Survey. *European journal of neurology*. 2012;19(1):163-7.
6. Suzuki J, Takaku A. Cerebrovascular moyamoya disease: disease showing abnormal net-like vessels in base of brain. *Archives of neurology*. 1969;20(3):288-99.
7. Smajlović D. Strokes in young adults: epidemiology and prevention. *Vascular health and risk management*. 2015; 11: 157-164.
8. Kaku Y, Morioka M, Ohmori Y, Kawano T, Kai Y, Fukuoka H, Hirai T, Yamashita Y, Kuratsu JI. Outer-diameter narrowing of the internal carotid and middle cerebral arteries in moyamoya disease detected on 3D constructive interference in steady-state MR image: is arterial constrictive remodeling a major pathogenesis?. *Acta neurochirurgica*. 2012;154(12):2151-7.
9. Tagawa T, Naritomi H, Mimaki T, Yabuuchi H, Sawada T. Regional cerebral blood flow, clinical manifestations, and age in children with moyamoya disease. *Stroke*. 1987; 18(5): 906-10.
10. Zipfel GJ, Fox DJ, Rivet DJ. Moyamoya disease in adults: the role of cerebral revascularization. *Skull Base*. 2005;15(01):27-41.
11. Li J, Jin M, Sun X, Li J, Liu Y, Xi Y, Wang Q, Zhao W, Huang Y. Imaging of moyamoya disease and moyamoya syndrome: current status. *Journal of Computer Assisted Tomography*. 2019;43(2):257-63.
12. Sugino T, Mikami T, Ohtaki S, Hirano T, Iihoshi S, Houkin K, Mikuni N. Assessment of moyamoya disease using multidetector row computed tomography. *Journal of Stroke and Cerebrovascular Diseases*. 2013;22(5):644-9.
13. Kim JE, Jeon JS. An update on the diagnosis and treatment of adult Moyamoya disease taking into consideration controversial issues. *Neurological research*. 2014;36(5):407-16.
14. Yamada S, Oki K, Itoh Y, Kuroda S, Houkin K, Tominaga T, Miyamoto S, Hashimoto N, Suzuki N. Effects of surgery and antiplatelet therapy in ten-year follow-up from the registry study of research committee on moyamoya disease in Japan. *Journal of Stroke and Cerebrovascular Diseases*. 2016;25(2):340-9.
15. Wei YC, Liu CH, Chang TY, Chin SC, Chang CH, Huang KL, Chang YJ, Peng TI, Lee TH. Coexisting diseases of moyamoya vasculopathy. *Journal of Stroke and Cerebrovascular Diseases*. 2014;23(6):1344-50.
16. Stone NJ, Robinson JG, Lichtenstein AH, Bairey Merz CN, Blum CB, Eckel RH, Goldberg AC, Gordon D, Levy D, Lloyd-Jones DM, McBride P. 2013 ACC/AHA guideline on the treatment of blood cholesterol to reduce atherosclerotic cardiovascular risk in adults: a report of the American College of Cardiology/American Heart Association Task Force on Practice Guidelines. *Journal of the American College of Cardiology*. 2014;63(25 Part B):2889-934.

17. Zarkali A, Brown N, Harding N, Grieve J, Adams M, Ganesan V, Simister R, Brown M. Long-Term Outcomes in Medically Treated Moyamoya Disease. *Journal of Neurology, Neurosurgery & Psychiatry*. 2016; 87(12): e1.
18. Jo KI, Yeon JY, Hong SC, Kim JS. Clinical course of asymptomatic adult moyamoya disease. *Cerebrovascular Diseases*. 2014;37(2):94-101.
19. Jang DK, Lee KS, Rha HK, Huh PW, Yang JH, Park IS, Ahn JG, Sung JH, Han YM. Bypass surgery versus medical treatment for symptomatic moyamoya disease in adults. *Journal of Neurosurgery*. 2016;127(3):492-502.
20. Scott RM, Smith ER. Moyamoya disease and moyamoya syndrome. *New England Journal of Medicine*. 2009;360(12):1226-37.
21. Miyamoto S, Yoshimoto T, Hashimoto N, Okada Y, Tsuji I, Tominaga T, Nakagawara J, Takahashi JC, Yamada K, Tomata Y, Fukui T. Effects of extracranial–intracranial bypass for patients with hemorrhagic moyamoya disease: results of the Japan Adult Moyamoya Trial. *Stroke*. 2014;45(5):1415-21.
22. Kim T, Oh CW, Kwon OK, Hwang G, Kim JE, Kang HS, Cho WS, Bang JS. Stroke prevention by direct revascularization for patients with adult-onset moyamoya disease presenting with ischemia. *Journal of neurosurgery*. 2016;124(6):1788-93.
23. Kronenburg A, Braun KP, van der Zwan A, Klijn CJ. Recent advances in moyamoya disease: pathophysiology and treatment. *Current neurology and neuroscience reports*. 2014;14(1):1-9.
24. Kazumata K, Ito M, Tokairin K, Ito Y, Houkin K, Nakayama N, Kuroda S, Ishikawa T, Kamiyama H. The frequency of postoperative stroke in moyamoya disease following combined revascularization: a single-university series and systematic review. *Journal of neurosurgery*. 2014;121(2):432-40.
25. Suwanwela NC, Nordli Jr DR. Moyamoya disease: Etiology, clinical features, and diagnosis. *UpToDate*. 2011; Waltham, MA, p. 4.
26. Ahn IM, Park DH, Hann HJ, Kim KH, Kim HJ, Ahn HS. Incidence, prevalence, and survival of moyamoya disease in Korea: a nationwide, population-based study. *Stroke*. 2014;45(4):1090-5.
27. Sucholeiki R, Chawla J, Stanley R. Moyamoya Disease. *Medscape* 9 Nov 2018. Accessed from: <http://emedicine.medscape.com/article/1180952-overview>