

Case Report

## Appropriate planning, thorough examinations and decent implementations for a predictable prognosis in the management of a severely worn dentition: A case report

Siti Mariam Ab Ghani\*<sup>1</sup> and Graeme Lillywhite<sup>2</sup>

<sup>1</sup>Head, Centre for Restorative Dentistry Studies, Faculty of Dentistry, Universiti Teknologi MARA, 40450 Shah Alam, Selangor, Malaysia

<sup>2</sup>Consultant, Restorative Department, Edinburgh Dental Institute, Edinburgh, United Kingdom

Institution: Centre for Restorative Dentistry Studies, Faculty of Dentistry, Universiti Teknologi MARA, 40450 Shah Alam, Selangor, Malaysia

---

**Abstract** The management of patients with severely worn dentition is challenging due to the loss of occlusal vertical dimension and tooth structure creating an uneven plane of occlusion. This case report describes the importance of every step of the conventional and improvised methods in treating tooth wear patients. Stages from the initial work-up of tooth wear assessment, substantial surgical crown lengthening, the controlled method of increasing vertical dimension, the precise method of crown preparations, advanced impression techniques till the cementation procedure of final restorations.

The whole treatment was in a reorganized approach such that the new inter-cuspal position (ICP) coincided with the retruded axial position (RAP). When restoring worn dentition, clinician should always have a proper planning, decent implementation for each stages thus guarantee excellent performances. However maintenance and recall visits are the main keys to long term success.

**Keywords:** crown lengthening, locating impressions, occlusal vertical dimension, tooth wear, silver dies

---

### Introduction

Tooth wear is a physiological loss of tooth structure due to prolong usage/ retain especially in the elderly. However, it can be regarded as pathological if the teeth become excessively worn and do not function effectively or affect the aesthetic appearances (Van't Spijker et al., 2007). The aetiology of tooth wear can be from erosion, abrasion, attrition and abfraction. *Erosion* is defined as loss of tooth structure due to acidic and non-bacterial tooth wear that can be cause by intrinsic and extrinsic factor. Extrinsic

causes are like diet (citrus and isotonic drinks), habits (swishing soft drinks and sucking sour foods) and occupation (swimmer in chlorinated pool water, battery factory worker, bar tender and wine tester).

Intrinsic causes of erosion can be related with medical history such as gastric reflux, bullimea, reduced salivary flow and pregnancy. Clinically, 'cupping' of the incisors (perimolysis) can be seen as the dentine has lower resistance to wear and erosion compared to enamel, matt surface of the enamel and dentine exposed with continuous erosion and 'proud' amalgam restoration. In intrinsic causes, the erosion is usually at the palatal of anterior teeth when the acid regurgitate forcibly. In extrinsic etiology, more surfaces are generally involved. *Attrition*

---

\*Correspondence to: Dr Siti Mariam Ab Ghani, Head, Centre for Restorative Dentistry Studies, Faculty of Dentistry, Universiti Teknologi MARA, 40450 Shah Alam, Selangor, Malaysia

Email: sitimariam783@salam.uitm.edu.my

Tel: +60355211955 (office)/+60122306980(mobile)

is caused by grinding and contact of teeth to teeth. It can be due to parafunctional such as bruxism and clenching, loss of posterior teeth resulting in higher occlusal load of anterior teeth, dentition opposed with ceramic crown and also in patient with malocclusion Class II Div II. The lesions clinically appear as well-defined wear facets on the functional surface matching of the wear facets of opposing dentition. The enamel and dentine wear at the same level. *Abrasion* is defined as loss of tooth structure due to excessive tooth and foreign object contact (Allen, 2003). The classical example is mechanical trauma from tooth-brushing and biting of foreign object such pipe in pipe smokers, pins for hairdresser or pens. *Abfraction* is loss of tooth structure at cervical area due to occlusal load with the clinical characteristic of wedge-shaped Class V lesion. During tensile

force, the enamel rods which are less elastic than dentine will fracture thus creating lesion at the cervical region. In daily practice, it is difficult to diagnose an initial tooth wear condition as sometimes patient does not recognize the sign and symptom themselves or might not volunteer to reveal sensitive condition as eating disorder. Smith and Knight (1984) did publish a tooth wear index (TWI) to help in diagnosis and monitoring of tooth wear. Each tooth have 4 surface recorded (cervical, labial, incisal/occlusal and lingual surfaces) with a value of 0-4. This TWI can be used to monitor individual patient by year recall or even produce profiles of tooth wear distribution in a specific group of patient. There are also other investigations that can be done for assessment of a potential tooth wear case prior achieving a definite diagnosis.

<p>Medical questionnaire - investigate gastric reflux condition, vomiting frequencies, psychological status.</p> <p>Mounted study cast on the articulator - occlusal and space analysis.</p> <p>Intra-oral photographs taken at interval time.</p> <p>Imaging - Peri-apicals (PA), Dentopantograph (DPT), Cone Beam Computer Tomography CBCT)</p> <p>Resting and simulated salivary flow test</p> <p>Diet diary- if suspected erosion elements</p>
--

**Table 1:** Additional investigations in tooth wear management

When the diagnosis is confirmed, the first step in tooth wear management is to avoid further tooth loss by addressing the aetiology. Once the aetiology and tooth wear is well controlled, the definitive treatment can be started. Treatment plan can be formulated after thorough investigations and discussion with the patient.

**Case Report**

Mrs. MS, a 45 year old female patient, was referred for the poor appearance of her upper front teeth which were worn down and sensitive to cold foods. The tooth surface loss had been identified and highlighted by her dentist one year previously who suggested that her high

daily intake of citrus fruits was the probable cause. MS reported that she was generally in good health, no known allergies to medications, non smoker and drinks alcohol occasionally.

**Examination And Findings**

*Extra-oral-* Patient has a skeletal pattern Class I with no adenopathy, trismus or facial asymmetry noted. The temporo-mandibular joint (TMJ) was not tender to palpation, no sounds and no deviation upon opening and closing the mouth. The amounts of maxillary teeth displayed during speech were very minimal with a reverse smile line.

**Intra-oral -**

- Occlusion - Class III incisal relationship - edge to edge (Fig. 1). Group function (canine and premolar guidance) in right and left excursions with minimal disclusion of posterior teeth. Mandible was easily manipulated into retruded axial position (RAP) with initial contact between the distal ridge of the 46 and the mesio-palatal cusp of 16
- Moderate to severe tooth surface loss was noted palatal to 13 to 23 (Fig. 2) with substantial loss of tooth structure and cupped appearance (perimolysis).
- Maxillary and mandibular posterior teeth had mild tooth surface loss. Slight cupping of cusp tips of premolars, intact and proud standing of amalgam restorations present with no marginal breakdown or secondary caries noted.

**Investigations**

*Sensibility test-* 13, 12, 11, 21, 22 and 23 showed positive responses to thermal and electric pulp testing.

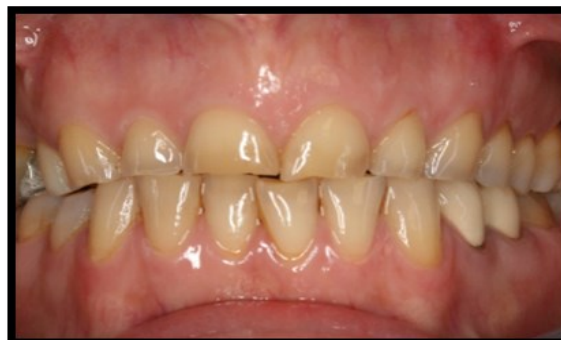*Radiographic investigations-* Radiographic examination of Dentopantograph (DPT) and periapical (PA) of 17 to 23 showed no periapical lesion, normal alveolar bone level and good root shape and length (Fig. 3)

*Articulated study casts-* Both casts were then mounted in RAP on a Denar Combi average value articulator with the aid of the face bow transfer. An occlusal record was taken using Moyco wax and Tempbond. First contact was noted between the distal ridge of the 46 and the mesio-palatal cusp of 16 (Fig. 4).

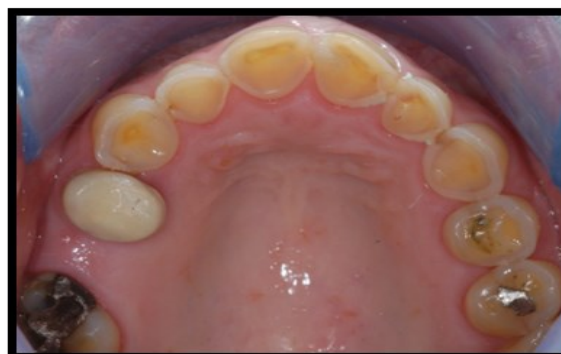*Diagnostic wax-up-* A preliminary diagnostic wax up was done at 2 mm increased occlusal vertical dimension (OVD). It was noticed at this stage that the maxillary incisors appeared squares and in order to achieve improved aesthetics, the length were increased 1 mm apically (Fig. 5).

**Diagnosis**

The diagnosed aetiology of the tooth wear was erosion with an element of attrition as a consequence to the softened tooth structure due to high intake of acidic food.



**Figure 1:** Short and yellowish appearance of the anterior teeth



**Figure 2:** Moderate to severe erosion of the palatal surfaces

**Figure 1 and 2:** Pre-operative photographs

**Restorative Management**

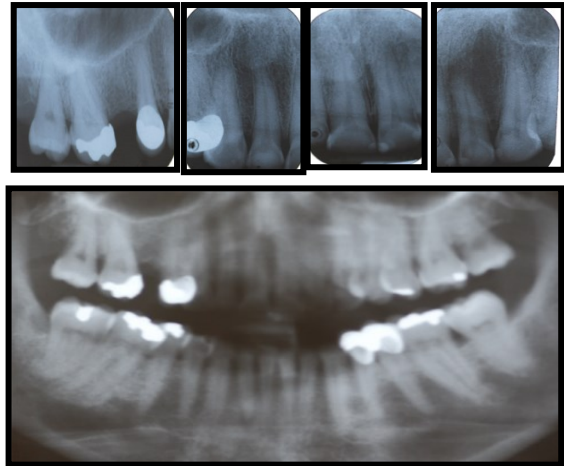
The main clinical and investigative findings were informed to Mrs. MS. Various treatment options were discussed and in order to fully address the issues and concerns raised by her, an extensive dental reconstruction was ideally the way forward. Her cooperation was essential in terms of attending the multiple visits and maintaining an excellent level of oral hygiene throughout the treatment.

<b>Stabilization phase</b>	<ul style="list-style-type: none"> <li>Preventive advice</li> <li>OHI and full mouth scaling and polishing.</li> </ul>
<b>Re-evaluation</b>	<ul style="list-style-type: none"> <li>Mock-up</li> </ul>
<b>Preliminary restorative phase</b>	<ul style="list-style-type: none"> <li>Replacement of amalgam restoration/core build-up 16</li> <li>Removal of crown 14 and assessment of underlying tooth preparation/coronal tooth structure</li> <li>Surgical crown lengthening from 14 - 23</li> </ul>
<b>Re-evaluation</b>	<ul style="list-style-type: none"> <li>OH, motivation and oral condition</li> </ul>
<b>Definitive restorative treatment</b>	<ul style="list-style-type: none"> <li>Ceramic bonded crowns for 13, 12, 11, 21, 22, 23</li> <li>Composite restoration at 41, 42, 31 and 32</li> <li>Metal ceramic bridge at 16 - 14</li> <li>Restoration of worn teeth 24 and 25</li> </ul>
<b>Maintenance phase</b>	<ul style="list-style-type: none"> <li>Occlusal splint</li> </ul>

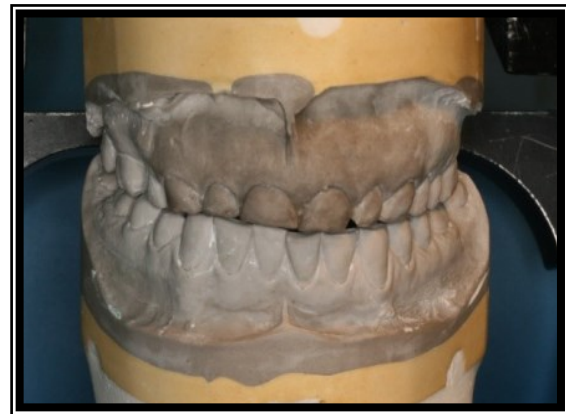**Table 2:** Key stages on management of the patient

**Intra-oral mock-up**

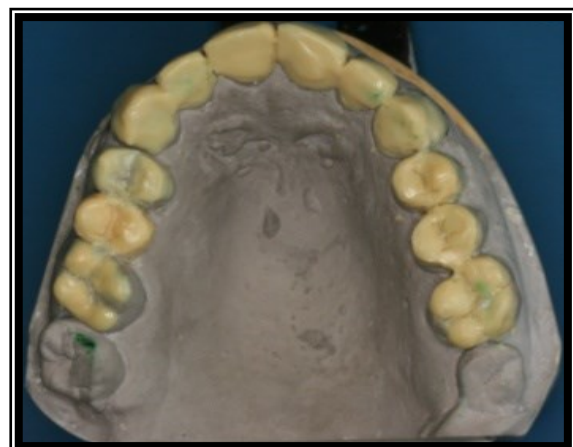Intra-oral mock-up is an effective tool for communication between dentist, patient and laboratory personnel. Assessment of the aesthetics and phonetics in relation with the soft tissues can be done. A silicone putty index of the diagnostic wax-up was filled with bis-acryl provisional C&B material (ProTemp) and seated over the maxillary teeth in order to assess the proposed appearance of the maxillary anterior teeth (Magne et al., 1996; Phuhong and Goldstein, 2007). Mrs. MS was very delighted with the proposed dental appearance (Figure 6).



**Figure 3:** Imaging (Periapicals, DPT)

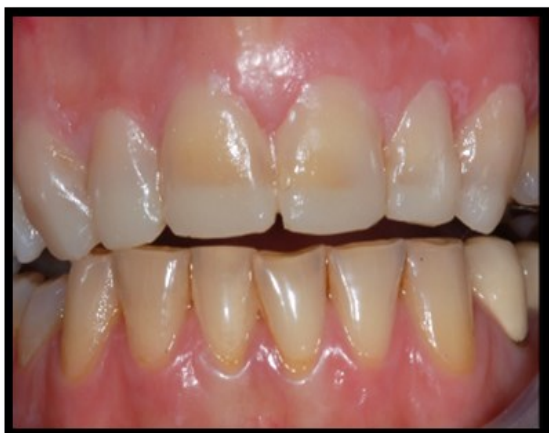

**Figure 4:** Articulated study casts



**Figure 5:** Diagnostic wax-up





**Figure 6:** Intra-oral mock-up

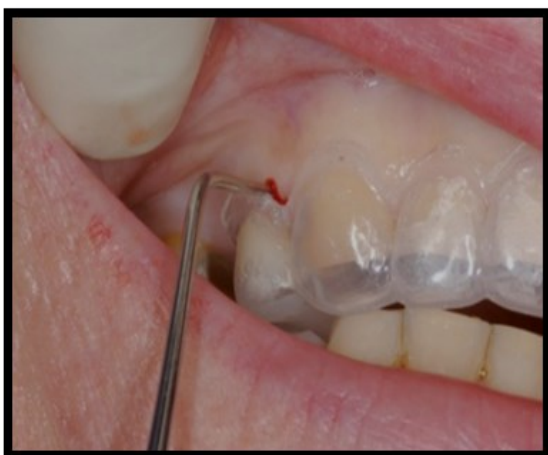**Figure 3 – 6.** Investigations for the management of tooth wear patients

#### **Surgical crown lengthening from 14 - 23**

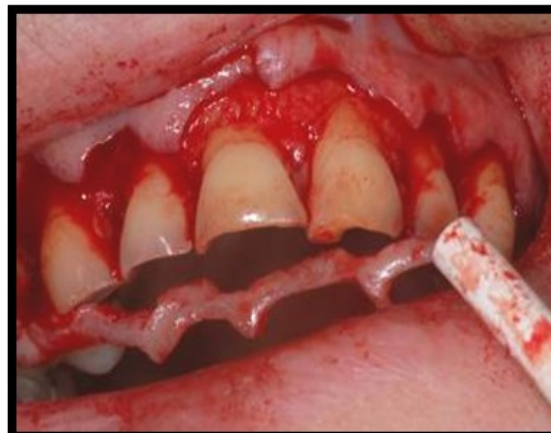Using the diagnostic wax-up, a surgical stent was fabricated to guide the amount of gingival and bone recontouring required. 3 mm of root surface allocated from the repositioned gingival margin to the alveolar crest (Gargiulo et al., 1961) Post-operatively instructions were given to the patient and four months were allowed for soft tissue healing before proceeding with treatment (Figure 7-8).

#### **Crown preparations and impression technique**

A silicone index (Fig. 9) fabricated from the diagnostic wax-up used as a guide to tooth



**Figure 7:** Incision level marked with surgical stent from diagnostic wax-up



**Figure 8:** Removal of soft tissue and alveolar bone recontouring

**Figure 7 – 8:** Procedure on crown lengthening

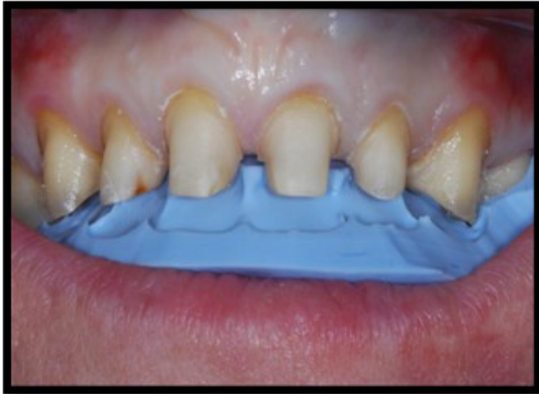reduction for teeth 16, 14, 13, 12 11, 21, 22 and 23 (Aminian and Brunton, 2003; Mizrahi, 2004). Individual impressions were made of the eight preparations using heavy/ light polyvinyl-siloxane (PVS) material. Retraction cord was placed alternately around the preparations during impression taking (Fig 10) and silver plated dies and impression transfer copings (DuraLay) were then fabricated. The impression transfer copings were verified on the crown preparations (13-23) intra-orally (Figure 11). These were then splinted together with stainless steel wire and self-curing acrylic resin for a locating impression made in PVS (Figure 12).

Working cast was poured from the locating impression and mounted on a semi-adjustable articulator with the aid of face bow transfer. A face bow taken with the tooth preparations (13-23) and relined with TempBond for precise detail of tooth preparation location (Figure 16-17).

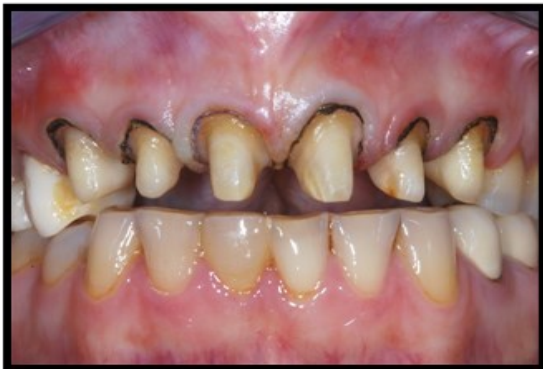#### **Increasing the occlusal vertical dimension (OVD)**

During provisional stage, a laboratory made maxillary anterior provisional crowns (Figure 13) were fitted at the increased OVD. Glass-ionomer stops were placed at 36, 37 and under rubber dam, composite restorations were placed on the 32-42 to level the incisal plane and stabilize the new OVD. The occlusion was adjusted so that intercuspal position (ICP)

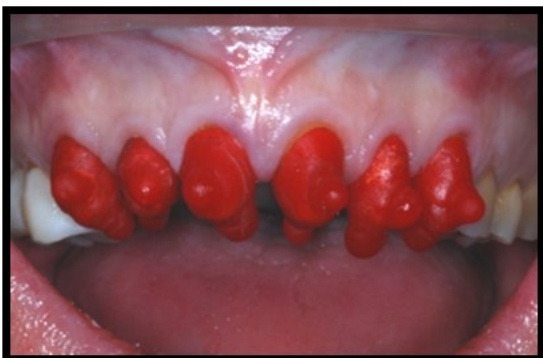coincides with RAP and canine guidance occlusion was provided. Patient was reviewed 2 weeks later and she reported no discomfort on the TMJ and had adapted well to the increased OVD. Phonetics was also satisfactory.



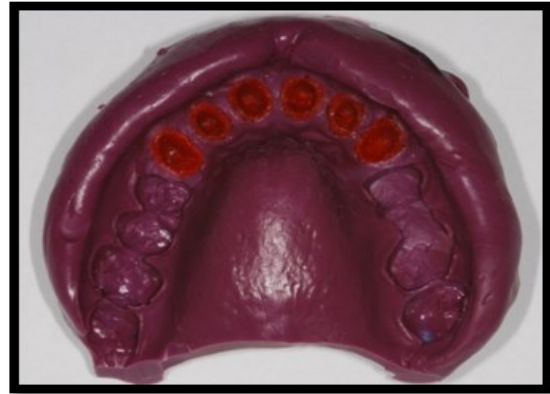
**Figure 9:** Preparations guided by silicone index from diagnostic wax-up



**Figure 10:** Gingival retraction to refine margin preparations

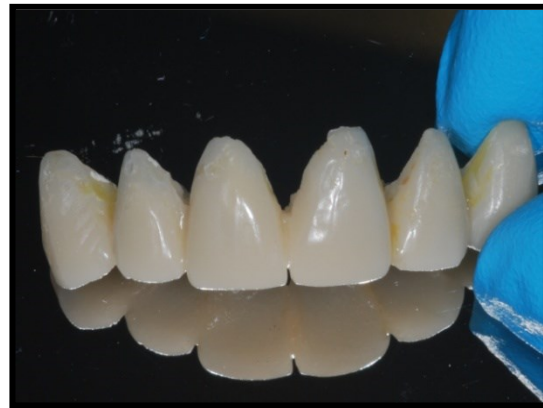

**Figure 11:** DuraLay resin coping try-in



**Figure 12:** Locating impression of six anterior crown preparations

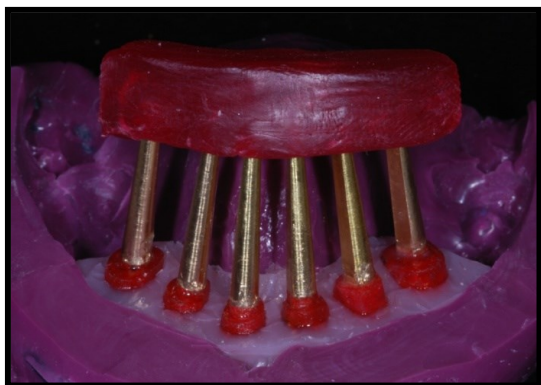**Figure 9 - 12.** Stages in preparation for full ceramic crowns



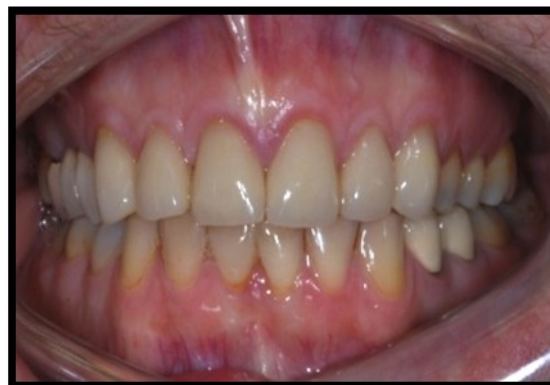**Figure 13:** Laboratory made provisionals



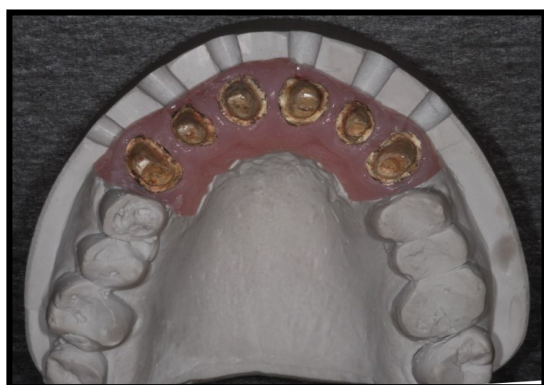**Figure 14:** Trimmed individual silver dies



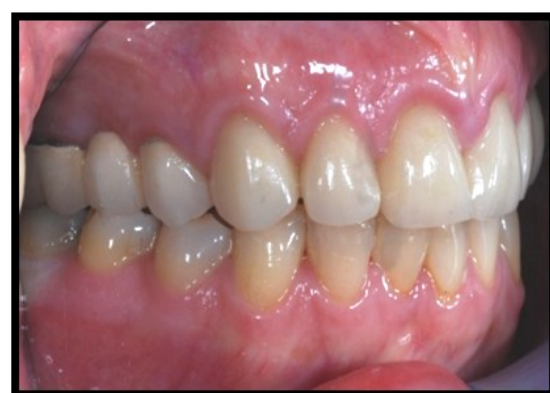**Figure 15:** Soft tissue mask applied prior cast pouring



Anterior view



**Figure 16:** Working cast ready for fabrication of the full ceramic crowns (6 anterior teeth)

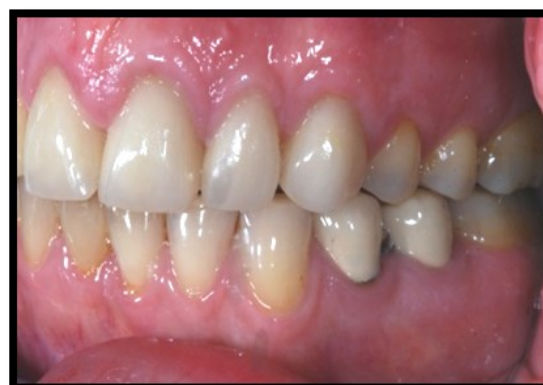

Buccal view (Right side)

**Figure 13– 16:** Advanced laboratory stages

**Final fit of restorations**

Once the all-ceramic crowns were ready (13, 12,11, 21, 22 and 23), try-in was done intra-orally for adjustment and finishing stage. The fitting surface was treated (9.6% HF followed by post-etching cleaning with phosphoric acid and silane added) prior cementation with resin luting cement under rubber dam. For the 14-16 metal-ceramic bridge, try in done and cemented with glass ionomer cements.



Buccal view (Left side)

**Figure 17:** Post-operative photographs



### Maintenance care

After fitting the restorations, the patient was given OHI with emphasis on the use of superfloss beneath the bridge 14-16. At review 2 weeks later the patient demonstrated an excellent level of oral hygiene and this was maintained. An occlusal splint was also provided to protect the oral reconstruction and patient arranged for further review visits.

### Discussion

The management of this patient's worn dentition was done in a controlled manner of increased OVD in order to create space for the restorations, avoid pulpal stress during tooth reduction and aligned the occlusal plane. Clinicians always worry that an increase in OVD will jeopardize the muscle activity thus result in tooth mobility, repeated restoration failure, TMJ disorder or myofascial pain. Patient adaptation is also a concern as there is no firm clinical recommendation available to determine if an increased OVD will be well adapted. An electromyograph (EMG) study found that the masticatory muscle can actually adapt well to an increased OVD as long as the increased is accompanied by a stable occlusion (Ramfjord et al., 1961). However, certain patients with OVD raised beyond their interocclusal distance do exhibit initial symptoms such as headache, clenching and grinding, muscle and joint fatigue, soreness of teeth, cheek biting, and problems with chewing and speech articulation for the first 2 days. However, there was no increase in the EMG of the masticatory muscle (Carlsson et al., 1979). In this case report, the increased OVD was done during provisional stage after tooth preparations and 1 month was given to assess the patient's adaptability.

Surgical crown lengthening (SCL) was carried out to improve both aesthetics and retention and resistance form of the tooth preparations. The usage of surgical stents was very important during the surgery to ensure the dimension provided does not invade the biological width. Further assessment should be done to evaluate suitability of the procedure prior com-

mencing the surgery. Assessments of the periodontal condition such as the bone level, periradicular lesion and gingival biotype was done clinically and radiographically (Ward, 1999).

Following crown preparation of the six maxillary anterior teeth and bridge 14-16, precaution that was taken to avoid unnecessary tooth reduction was by having an index. An index made from the diagnostic wax up was very beneficial because sometimes the worn areas do not require any tooth reductions. Tooth structure was preserved as much as possible and the pulpal status remained healthy.

As for the impression stage, it was difficult to obtain accurate impressions of the 6 anterior teeth preparations in a single impression. Thus, locating impression was made. Other advantages from this technique were it allows for verification of the final restorations margin with the DuraLay copings, facilitates impression making, minimizes gingival trauma from the use of retraction cord in the final impression and record gingivae in their normal position. (Fig. 13-16)

A full ceramic (lithium disilicate) was the chosen material for the anterior crowns for its aesthetics and the capability to be bond to tooth structure. Different type of etchable ceramics when bonded to tooth surface exhibit similar flexural strength among them and also as in natural tooth (Burke, 1999). Ceramic surface treatment with hydrofluoric acid (HF) and silane application does increase the microtensile bond strength between ceramic and resin cements. Factors that are essential for success when using all-ceramic restorations have been identified by many authors such as the precise attention to detail with regard to tooth preparation, cervical margin design and location, soft-tissue management and impression-making. Proper selection of materials and the ceramist also are essential, as are correct shade matching procedures and correct luting protocols ensure the long-term success (Donovan, 2008).

The whole restorative treatment for this patient was done in reorganized approach such that the new ICP coincided with the RAP. Canine guidance also known as mutually protected



occlusion was provided to the patient. Mutually protected articulation is described as “an occlusal scheme in which the posterior teeth prevent excessive contact of the anterior teeth in maximum intercuspation, and the anterior teeth disengage the posterior teeth in all mandibular excursive movements” (Glossary of Prosthodontics, 2008). After completing the case, the glass-ionomer (GIC) stops on 36 and 37 (stops that hold the new OVD) were removed. As expected, these teeth were not in occlusion but contact re-establishment did occur during the review visit (4 weeks post treatment). The concept of relative axial tooth movement (RATM) was applied (Poyser et al., 2005). It is a concept introduced by Dahl in 1975 when they found that tooth with filling/ restoration in high contact display intrusion and tooth not in contact display extrusion movement to be in contact.

### Conclusion

By applying all the described techniques in the treatment procedure, the clinician had a good controlled of the case, able to provide decent execution of each procedure and reduced the risk of complications. Patient did come for additional visits with longer treatment time and increased cost, however it was emphasized that the final results with predictable prognosis was the ultimate treatment outcome. Mrs MS was pleased with the treatment outcome in terms of appearance, masticatory function, speech and comfort (Fig. 17). She was reviewed after 2 years and reported no complications. The prognosis of the restorations was considered to be very good however maintenance and recalls were essential. However, the result was from a single case report, therefore further cases required before coming to the conclusion that all the described stages is a must or highly advisable to ensure a good prognosis of the restorations in the management of tooth wear.

### References

1. Van't Spijker A, Kreulen CM and Creugers NH. Attrition, occlusion, (dys)function and intervention: a systematic review. **Clin Oral Implants Res** 2007. **18 (Supp 13)**, 117-126
2. Allen PF. Use of Tooth-coloured Restorations in the **Management of Toothwear. Dent Update** 2003. **30**, 550–556
3. Magne P, Magne M and Belser U. The diagnostic template: **A key element to the comprehensive esthetic treatment concept. Int J Periodontics Restorative Dent** 1996; **16**, 560-590
4. Phuhong DD, Goldstein GR. The use of a diagnostic matrix in the management of the severely worn occlusion. **J Prosthodont** 2007. **16**, 277-281
5. Gargiulo AW, Wentz F and Orban B. Dimensions and relations of the dentogingival junction in humans. **J Periodontol** 1961. **32**, 261–267
6. Aminian A, Brunton PA. A comparison of the depths produced using three different tooth preparation techniques. **J Prosthet Dent.** 2003 Jan. **89(1)**, 19-22
7. Basil Mizrahi. A Technique for Simple and Aesthetic Treatment of Anterior Toothwear. **Dent Update** 2004. **31**, 109–114
8. Ramfjord SP. Dysfunctional temporomandibular joint and muscle pain. **J Prosthet Dent** 1961. **11**, 353-374
9. Carlsson GE and Kocal G. Effect of increasing vertical dimension on the masticatory system in subjects with natural teeth. **Journal of Prosthetic Dentistry** 1979. **41**, 284-289
10. Ward VJ. Tooth surface loss. Surgical crown lengthening. **Br Dent J.** 1999 Jul **10. 187(1)**, 21-24
11. Burke FJ. Maximising the fracture resistance of dentine-bonded all-ceramic crowns. **J Dent.** 1999 Mar. **27(3)**, 169-73
12. Donovan TE. Factors Essential for Successful All-Ceramic Restorations. **J Am Dent Assoc** 2008. **139**, 14S-18S

13. The Glossary of Prosthodontic Terms. 8th Edition. **J Prosthet Dent** **2005. 94**, 10-92
14. Poyser NJ, Porter RW, Briggs PF, Chana HS, Kelleher M and Patel M. The Dahl Concept: past, present and future. **Br Dent J** **2005.198**, 669–676
15. Dahl BL, Krogstad O and Karlsen K. An alternative treatment in cases with advanced attrition. **J Oral Rehabil** **1975. 2**, 209–214