

Interdisciplinary Approach Involving Medical Colleagues in Managing Periodontitis Patient with Type 2 Diabetes: A Case Report

Nur Zety Mohd Noh^{1,2}, Mohd Faizal Hafez Hidayat^{1*}, Farha Ariffin¹, Erni Noor¹, Fouad Hussain Al-Bayat¹

¹Centre of Periodontology Studies, Faculty of Dentistry, Universiti Teknologi MARA Sungai Buloh Campus, Jalan Hospital, 47000 Sungai Buloh, Selangor, Malaysia.

²Department of Restorative Dentistry, Kulliyah of Dentistry, International Islamic University Malaysia, Kuantan Campus, Jalan Sultan Ahmad Shah, Bandar Indera Mahkota, 25200 Kuantan, Pahang, Malaysia

Corresponding Author:

faizalhafez@uitm.edu.my

Tel: +60361266463

Received: September 03, 2021

Accepted for publication: November 06, 2021

DOI: <https://doi.org/10.24191/cos.v9i1.16914>

ABSTRACT

Introduction: *Diabetes mellitus has been recognized as a systemic risk factor for periodontitis. Success in controlling periodontitis requires interdisciplinary solutions involving medical counterparts.* **Case report:** *This case report highlights the importance of a bidirectional communication between medical and periodontal specialist in the management of a 63-year-old Malay lady patient diagnosed with Generalized Periodontitis, Stage IV and Grade C. The outcome of the interdisciplinary approach was both the stabilization of her periodontal conditions and medically, the glycated haemoglobin level.* **Conclusions:** *The bidirectional communication between medical and periodontal specialist is as important as managing the patients medically for a holistic treatment approach of an uncontrolled diabetic patient.*

Keywords: *diabetes; interdisciplinary; periodontal medicine; periodontitis*

Abbreviations: *bleeding on probing (BOP), body mass index (BMI), glycated haemoglobin (HbA1c), non-surgical periodontal therapy (NSPT), periodontal probing pocket depth (PPD), scaling and root debridement (SRD)*

INTRODUCTION

Periodontal disease is a chronic inflammatory disease that affects supporting structures of teeth caused by dental biofilm while diabetes mellitus is a metabolic disorder characterized by hyperglycaemia that is deemed as one of the systemic risk factors of periodontal disease. Both diseases are acknowledged as a global burden due to the high incidence of cases (Preshaw et al. 2011). This emphasizes the role of dental and medical professionals in managing the patients. Therefore, this case report is aimed to highlight the relationship between diabetes mellitus and periodontitis, the importance of communication between both specialties in managing diabetic patients with periodontitis, and to acknowledge the medical colleagues that referral of diabetic patients to periodontists is as important as managing the patients medically.

CASE REPORT

A 63-year-old Malay lady had undergone periodontal treatment at the Spinel Postgraduate Periodontics Clinic with her consent since November 2018 for management of residual deep periodontal pockets. She was diagnosed with Type 2 diabetes mellitus since 2015 and is currently on 1 g metformin twice daily. Full mouth periodontal examination revealed deep probing periodontal pocket depth (PPD) ranging from 5 mm to 8 mm with bleeding on probing (BOP). As shown in Figure 1, radiograph taken in November 2018 demonstrated periodontitis due to the presence of alveolar bone loss. Based on clinical examinations and radiographic investigation, she was diagnosed with Generalized Periodontitis, Stage IV, Grade C (Tonetti et al. 2018).

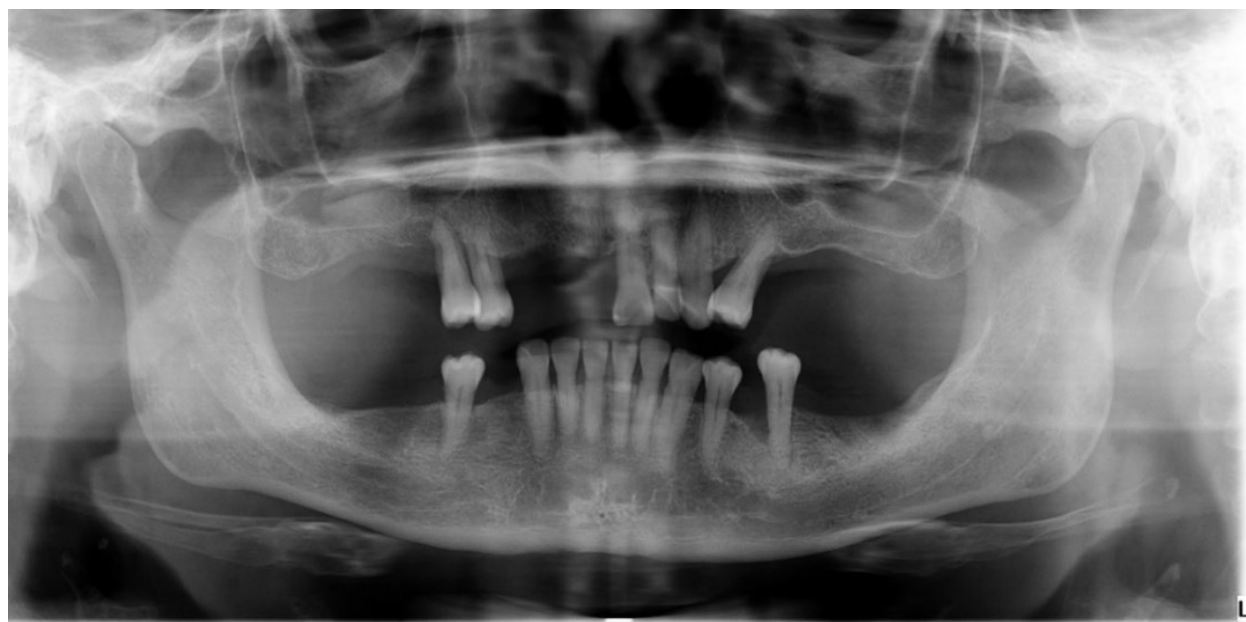

Figure 1. Baseline panoramic radiograph of the patient showing generalized horizontal bone loss and vertical bone loss on mesial root surface of lower left second premolar tooth

During the patient's initial visit to the periodontal clinic, random blood glucose level was measured instead of fasting blood glucose as a routine procedure prior to treatment of a diabetic patient. She was referred to a medical colleague regarding her high random blood glucose level of 21.2 mmol/L and the

requested glycated haemoglobin (HbA1c) test showed the reading of 10.4 %. Her periodontal condition was also highlighted and updated in correspondence (by letter every six months) with the medical colleague when the patient went for her medical regular check-up. Interdisciplinary management between medical and dental team includes lifestyle changes and diet consultation such as brisk walking, increased intake of fruits and vegetables as well as intake of brown rice instead of white rice with the provision of periodontal treatment. The non-surgical periodontal therapy (NSPT) that includes oral hygiene instruction as well as scaling and root debridement (SRD) were provided to the patient. She was reviewed every three months to monitor her periodontal disease condition.

Indeed, her periodontal condition improved following several NSPT visitations without the need of surgical intervention. The baseline BOP of 41.1 % reduced to 10 % in July 2020 and the deepest periodontal PPD was 4 mm with absence of BOP. Patient is deemed to have periodontal stability on a reduced periodontium (Lang and Bartold 2018). As shown in Figure 2, increased radiopacity of a vertical bone defect at the mesial aspect on the lower left second premolar may indicate new bone fill. In addition, as highlighted in Table 1, her baseline HbA1c improved from 10.4 % to 7.8 % in July 2020.

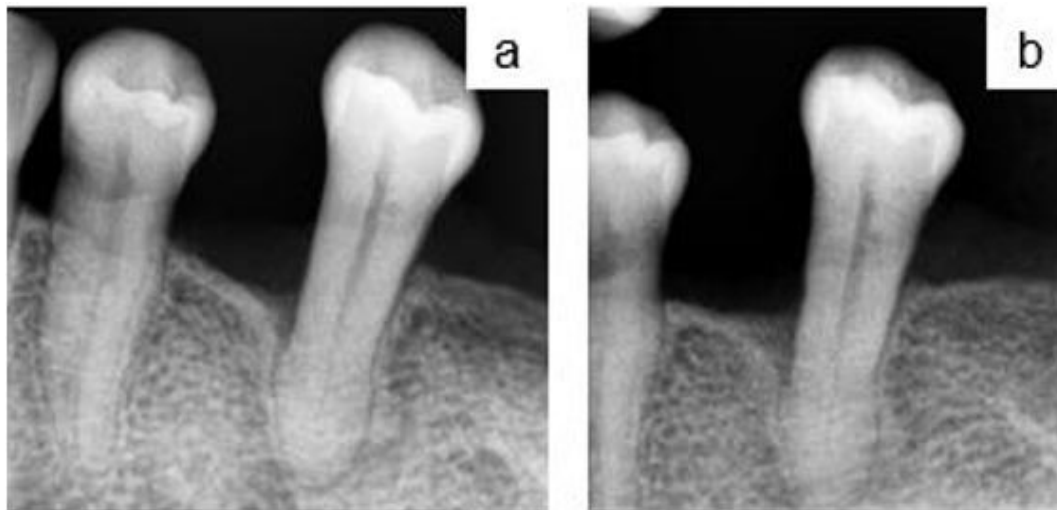


Figure 2. Periapical radiograph on lower left second premolar at (a) 15 months of review; (b) 22 months of review

Table 1 Summary on HbA1c level of the patient.

Date	Reading of HbA1c
November 2018	10.4 %
May 2019	8.5 %
December 2019	8.6 %
April 2020	8.9 %
July 2020	7.8 %

DISCUSSION

Classic studies had been conducted on the Gila River Indian community to find the association between diabetes mellitus on periodontal condition (Nelson et al. 1990; Emrich et al. 1991). First, diabetes mellitus causes microvascular changes with increased formation of the advanced glycation end products, which consequently enhance periodontal destruction (Preshaw et al. 2011). Second, diabetes mellitus is associated with impaired immune response and defective healing (Graves et al. 2020). Hyperglycaemia also affects bone equilibrium due to increased osteoclast formation (Graves et al. 2020; Preshaw et al. 2011). On the other hand, periodontitis renders diabetic condition worse by acting as a source of proinflammatory mediators that affect insulin signalling, thus consequently reduce glucose uptake by cells and insulin sensitivity, resulting in worsened glycaemic control of the patient (Genco et al. 2020). This relationship is manifested by the patient as she was presented with generalized periodontitis with uncontrolled Type 2 diabetes mellitus.

According to the patient, her diabetic regime remained the same in terms of antidiabetic medication since 2015. She has been given advice to increase the intake of fruits and vegetables as well as brown rice instead of white rice in her diet. She was also advised to be active everyday by exercising such as brisk walking. However, the patient was queried whether she was able to comply with the instructions as a means to improve her diabetic condition. Another aspect is the body mass index (BMI), which reflects body fat measurement in relation to the height and body weight. There is an association between obesity, diabetes mellitus and periodontitis (Saito and Shimazaki 2007). In the body of obese patients, adipocytes get larger, thus increase the proinflammatory cytokines production. Consequently, this affects insulin sensitivity and glucose metabolism, thus worsening the diabetic condition (Suvan, Finer, and D'Aiuto 2018). However, BMI reading of the patient was not provided to establish this relationship.

According to the American Diabetes Association (2005), HbA1c level of less than 7 % indicates the patient's diabetic condition is controlled. However, higher than 7 % HbA1c level indicates an uncontrolled diabetic condition of a patient. In treating this patient, there was a dilemma to proceed with non-surgical or surgical periodontal treatment, especially on tooth 35 with deep PPD and vertical bone defect. Previous treatment approach usually focuses on eliminating vertical bone defects through open flap surgery or ostectomy, while the recent approach is focusing on guided tissue regeneration therapy (Cortellini and Tonetti 2000). However, there are many factors to be considered such as bacterial contamination, innate wound healing potential, local site characteristics and surgical procedure prior to surgical planning (Kornman and Robertson 2000). As for this patient, her uncontrolled diabetic condition was a concern and may contribute to deep wound infection and impaired healing following surgical procedure.

Even though NSPT is the gold treatment standard, it has its limitation especially in the area with deep periodontal pocket, multi-rooted teeth or furcation involvement (Graziani et al. 2017). However, a successful treatment outcome is still achieved especially in the single rooted teeth (Badersten, Nilveus, and Egelberg 1984). NSPT can reduce probing PPD and frequency of BOP and gain in the clinical attachment level (Graziani et al. 2017). After several non-surgical treatment appointments, the patient has shown an improvement in which the BOP reduced from 41.1 % at baseline to 10 % during the latest periodontal review with reduced probing PPD. The patient is currently presented with periodontal stability on reduced periodontium (Lang and Bartold 2018) as absence of BOP is an indicator of periodontal stability (Lang et al. 1990).

Based on previous discussions and findings, it was reported that the provision of dental treatment may assist in restoring insulin sensitivity, metabolic control and periodontal clinical parameters (Preshaw et al. 2011; Grossi et al. 1997; Westfelt et al. 1996). However, further studies shall be conducted to investigate the outcome as restoration of metabolic control can be multifactorial. In addition to medical management, this shows that periodontal treatment can play its part in managing diabetic patients. However,

inadequate communication between medical professionals and periodontists as well as lack of awareness and knowledge on periodontal health pertaining to systemic issue among medical colleagues may limit the provision of a holistic treatment management for the patients. On the other hand, the knowledge on periodontitis-diabetes relationship helps to alert the medical professionals that diabetic patients have higher risk of periodontitis. Therefore, they can play their role in periodontal health by providing early referral for periodontal screening to benefit the patients (Ramirez et al. 2010; Dubar et al. 2019).

CONCLUSIONS

A bidirectional communication between medical professionals and periodontists is as important as managing the patients medically for a holistic treatment approach. Patients can benefit from the screening and referral of periodontal treatment by medical professionals to assist in improving patients' glycaemic control and periodontal health towards a better quality of life.

CONFLICT OF INTEREST

The authors claimed no conflict of interest.

REFERENCES

- Badersten A, Nilveus R, and Egelberg J (1984) Effect of nonsurgical periodontal therapy II. Severely advanced periodontitis. *J. Clin. Periodontol.* 11: 63–76.
- Cortellini P and Tonetti MS (2000) Focus on intrabony defects : guided tissue regeneration. *Periodontol.* 2000. 22: 104–132.
- Dubar M, Delatre V, Moutier C, Sy K, and Agossa K (2019) Awareness and practices of general practitioners towards the oral-systemic disease relationship : A regionwide survey in France. *J Eval Clin Pract.* 26(6):1-9.
- Emrich LJ, Shlossman M, and Gencox RJ (1991) Periodontal disease in non-insulin- dependent diabetes mellitus. *J Periodontol.* 62:123-130.
- Genco RJ, Graziani F, and Hasturk H (2020) Effects of periodontal disease on glycemic control, complications, and incidence of diabetes mellitus. *Periodontol 2000.* 83(1):59-65.
- Graves DT, Ding Z, and Yang Y (2020) The impact of diabetes on periodontal diseases. *Periodontol 2000.* 82(1):214-224.
- Graziani F, Karapetsa D, Alonso B, and Herrera D (2017) Nonsurgical and surgical treatment of periodontitis : how many options for one disease?. *Periodontol.* 2000. 75: 152–188.
- Grossi SG, Skrepcinski FB, DeCaro T, Robertson DC, Ho AW, Dunford RG, Genco RJ (1997) Treatment of periodontal disease in diabetics reduces glycated hemoglobin. *J. Periodontol.* 68: 713–719.
- Kornman KS and Robertson PB (2000) Fundamental principles affecting the outcomes of therapy for osseous lesions. *Periodontol.* 2000. 22: 22–43.
- Lang NP, Adler R, Joss A, and Nyman S (1990) Absence of bleeding on probing: An indicator of periodontal stability. *J. Clin. Periodontol.* 17(10): 714–721.

- Lang NP, and Bartold PM (2018) Periodontal health. *J Clin Periodontol.* 89(S1):9-16.
- Nelson RG, Shlossman M, Budding LM, Pettitt DJ, Saad MF, Genco RJ, and Knowler WC (1990) Periodontal disease and NIDDM in Pima Indians. *Diabetes Care.* 13(8):836-840.
- Preshaw PM, Alba AL, Herrera D, and Jepsen S (2011) Periodontitis and diabetes : a two-way relationship. *Diabetologia.* 55:21-31.
- Ramirez JH, Arce R, and Contreras A (2010) Why must physicians know about oral diseases ? *Teach Learn Med.* 22(2):37-41.
- Saito T and Shimazaki Y (2007) Metabolic disorders related to obesity and periodontal disease. *Periodontol.* 2000. 43: 254–266.
- Suvan JE, Finer N, and D’Aiuto F (2018) Periodontal complications with obesity. *Periodontol.* 2000. 78: 98–128.
- Tonetti MS, Greenwell H, and Kornman KS (2018) Staging and grading of periodontitis : Framework and proposal of a new classification and case definition. *J Clin Periodontol.* 89(S1):149-161.
- Westfelt E, Rylander H, Blohme G, Jonasson P, and Lindhe J (1996) The effect of periodontal therapy in diabetics. Results after 5 years. *J. Clin. Periodontol.* 23: 92–100.