

Management of C-shaped canals using “Membrane-Barrier Technique”: A Case report

Afzan Adilah Ayoub^{1,2,*}, Gary Shun-Pan Cheung²

¹*Comprehensive Care Centre of Studies, Faculty of Dentistry, Universiti Teknologi MARA Sungai Buloh Campus, Jalan Hospital, 47000 Sungai Buloh, Selangor, Malaysia*

²*Department of Endodontology, Faculty of Dentistry, University of Hong Kong, Hong Kong*

Corresponding Author:

afzan_adilah@uitm.edu.my

Tel: 603 6126 6603

Fax: 603 6126 6103

Received June 25, 2021:

Accepted for publication: Aug 20, 2021

DOI: <https://doi.org/10.24191/cos.v9i1.16912>

ABSTRACT

A 61-year old Chinese female was referred from a general private practitioner for persistent buccal abscess after completion of root canal treatment of tooth 37. On clinical examination, tooth 37 presented with a metal-ceramic crown (CMC) with 2mm of gingival recession noted at the buccal region. The overlying amalgam core was overhanging on distal and grade 2 mobility. The 37 CMC have no contact point at the distal. Tooth 37 was not tender to palpation but tender to percussion. No periodontal pocketing was detected. The periapical radiograph revealed a periapical radiolucent area associated end of its root. These 37 apices were resorbed, probably a result of the apical periodontitis there. Widening of periodontal space was noted with this 37. A diagnosis of chronic apical periodontitis with external resorption of root apices with a C-shaped canal was made for the tooth 37. Membrane barrier technique with MTA was used for obturation. A bonded amalgam core was placed in this tooth.

Keywords: *C-shaped canals, endodontics, external resorption, membrane barrier technique*

INTRODUCTION

External root resorption may manifest as aftermath of dental trauma, orthodontic treatment (Gartenr et al.1976), microorganism infection or improper sealing of root canal. The root cementum and dentin are resorbed followed by root resorption (Berman & Hargreaves,2015). There is crater deformation on the resorptive region. This may cause deformation of the root apex and lead to losing the apical constriction. It is crucial to consider that external resorption may not only be a consequence of trauma. But as the father of

injury, Andreasen stated it may also subsequently after an injury to periodontal ligament which is related to periodontic, pedodontic, orthodontic or endodontic procedures (Andreasen et al, 2018). At the apical region, early necrosis of the pulp tissue or in complete root formation and external resorption may show a blunted or shortened root with a wide-open foramen (Araujo et al,2010). In the present case, owing to a faulty initial root canal treatment implemented, complicated C-shape canal along with incomplete sealing of the root canal treatment, reinfection is liable to occur, leading to apical resorption. Non-surgical root canal treatment was therefore indicated. The tooth presented with a wide apical foramen, with morphologic deformities, making it a challenge in obtaining a good apical seal.

CLINICAL CASE REPORT

A 61-year-old Chinese female was referred from a general private practitioner for persistent buccal abscess after completion root canal treatment of tooth 37. Upon external examination, her face is symmetry. No clicking, no tenderness to palpation and no deviation upon opening and closing detected with her temporomandibular joints. No lymphadenopathy was detected in her submental, submandibular and cervicular region. The root canal treatment of tooth 37 was completed 10 years ago by a private practitioner. She was complaining of persistent swelling on and off in the last 2 years ago. Patient is a housewife. She is a non-smoker, with no parafunctional habit. Her past medical history included a controlled hypertension and cholesterol level. The patient was a regular dental attendee and keen to keep her dentition intact as long as possible.

The patient's oral hygiene was considered good with generalized mild deposit of plaque. All permanent teeth were present except tooth 28. There were generalized incisal and occlusal wear. Tooth 11 was chipped off at the incisal third (Figure 1). CMC was placed on tooth 37(Figure 2). Arrested caries were detected on occlusal of teeth 38 and 48. Periodontal probing in all teeth was 3 mm or less and normal mobility was detected in all teeth

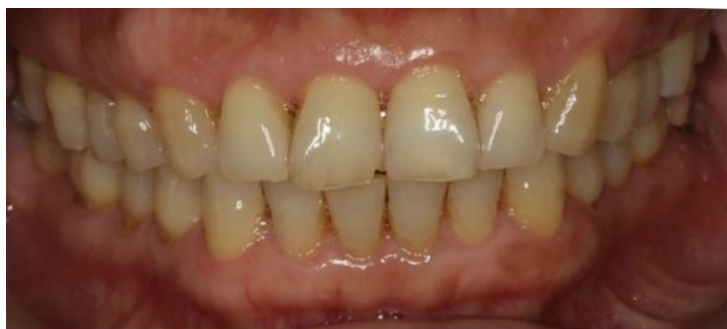

Fig.1 Clinical frontal view

Upon clinical examination, tooth 37 presented with 2 mm of gingival recession noted at the buccal region. The overlying amalgam core was overhanging on distal and grade 2 mobility. The 37 CMC have no contact point at the distal. This tooth 37 was non- tender to palpation but tender to percussion. No periodontal pocketing was detected.

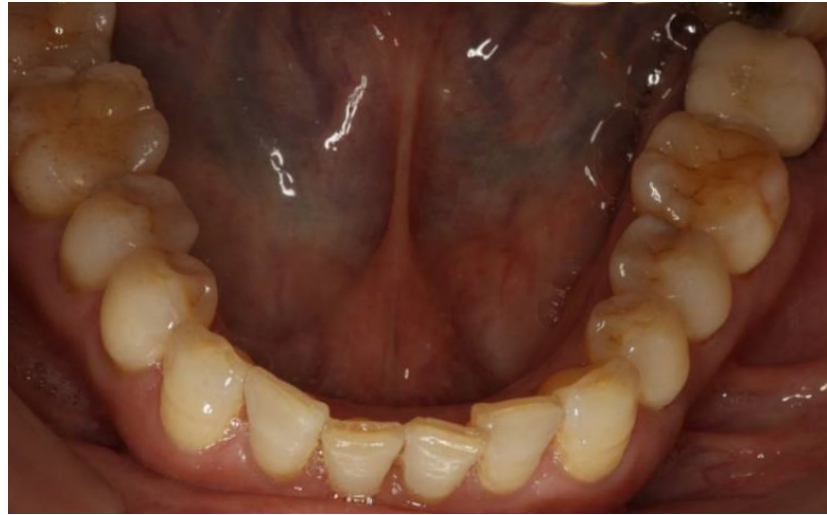
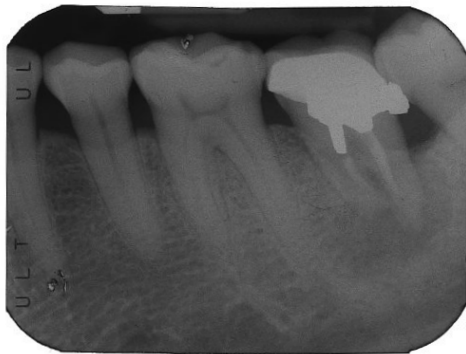
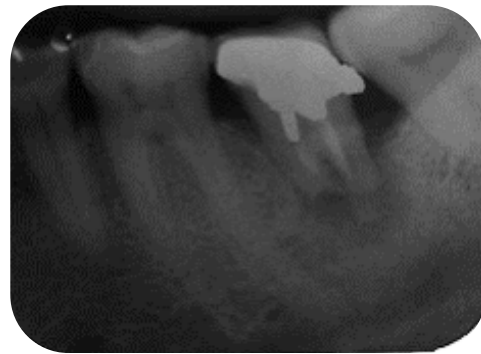Fig.2 Clinical occlusal view of upper and lower arch

Periapical radiograph revealed a periapical radiolucent area associated end its root (Figure 3 and 4). The tooth had been treated five years before. These 37 apices were resorbed, probably a result of persistent apical periodontitis there. Widening of periodontal space was noted with this tooth 37. A diagnosis of chronic apical periodontitis with external resorption of root apices complicated with a C-shaped canal was made for the tooth 37. The patient was advised on the clinical findings and various treatment options were discussed including non-surgical root canal retreatment, no treatment at all or tooth extraction. All the technical challenges and potential risks of the procedure had been explained to the patient. She had given consent for the best potential method to preserve her tooth via a non-surgical root canal retreatment despite extraction. She persistently expressed the desire to maintain a functional tooth if possible without any extraction intervention. Due to the-nature of apical resorption, membrane barrier technique with Mineral Trioxide Aggregate (MTA) as the technique of obturation followed by a bonded amalgam core was recommended for this tooth.



**Fig. 3 Pre-operative radiograph-
from referring dentist**



**Fig. 4 Pre-operative radiograph of
tooth 37 – one year after**

Treatment details

Non-surgical root canal retreatment of tooth 37 was performed under the inferior dental block and buccal infiltration (Xylocaine[®] with 1:80,000 adrenalines), rubber dam isolation and magnification from a dental operating microscope. Access cavity was prepared after dismantling the metal-ceramic crown of tooth 37 and old coronal restoration were removed and restored with GIC, stabilized with an orthodontic band. The periphery of the access cavity was redefined to facilitate straight line access. The pulp chamber floor was a C-shaped canal cross-section with 2 canals, which were already root treated. The old root fillings were removed with H-files and solvent. Both canals were irrigated by 2.0% chlorhexidine and physiological saline to avoid any mishap. The working length for all canals was measured with an electronic apex locator (Root ZX Apex Locator, J Morita Corporation, Kyoto, Japan) and confirmed with a periapical radiograph. Patency was established with a size 10 K-file and the canals were prepared by the step down technique⁵. The fins between two canals and the mid buccal canal were instrumented using a size no. 20 endosonic file in a low power setting of the ultrasonic unit (Piezon 400, EMS SA, Nyon, Switzerland). The master apical file size of the mesiobuccal canal was 50 and the distobuccal canal was 55 (Figure 5). The canals were frequently flushed with 3% sodium hypochlorite with ultrasonic activation and ethylene-di-amine-tetraacetic acid (17%) solution followed by physiological saline and final flush by 2% chlorhexidine digluconate. Geitslich Bio-Gide[®] (Geitslich Pharma AG, Bahnhofstrasse, Wolhusen, Switzerland) were cut into a small square as membrane barrier. It was adapted on the smallest plugger available to the working length. Bleeding was initiated earlier by using size 45 K-file and DG-16, ensuring a moist environment for the membrane and a thick mixture of White ProRoot MTA (Dentsply, Switzerland) placement. Both canals were obturated up to 5 mm of MTA (Figure 6). MTA carrier was used followed by activation by ultrasonic and plugger to ensure a properly packed MTA. A moist cotton pellet was placed to stimulate the setting of MTA. The canals were back filled with thermoplasticized injectable gutta-percha technique (Obtura II system)

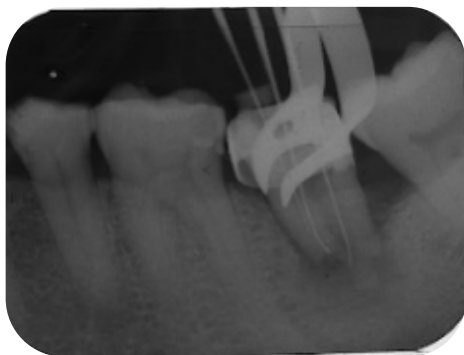


Fig. 5 Working length of tooth 37

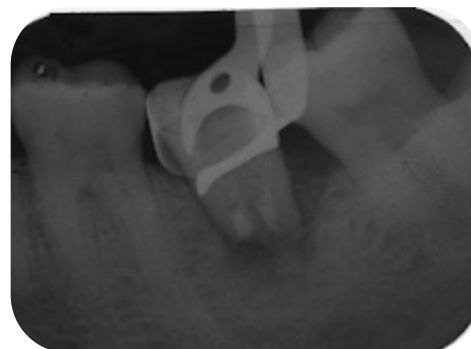

Fig.6 5-mm of MTA placement

Non-setting calcium hydroxide (Calasapt[®]) was used as intra-canal medicaments. All inter-appointment temporization was carried out with a cotton-pellet, Cavit[®] (ESPE, Seefeld, Germany) and IRM[®] (Intermediate Restorative Materials, Caulk.Co, Mildford, Del). Approximately 1 to 2 mm of IRM[®] was placed over the root filling of all canals leaving about 1 to 2 mm space coronally for the radicular-bonded amalgam. The tooth 37 was restored with a bonded amalgam core and a post-operative radiograph was taken. Patient was advised to return to the referring dentist for further management of tooth 37. Upon completion of the non-surgical root canal retreatment, the prognosis of 37 was considered guarded (Figure 7).

After 7-months, the patient had no complaint, and the tooth was not tender to palpation or percussion. There was no sinus tract noted but no crown was placed. Periodontal probing depths were 3

mm or less and no mobility associated with the tooth. The condition of the tooth was considered good despite a guarded prognosis given earlier. Radiographically, healing was evident by a reduction in the size of the periapical lesion (Figure 8). The patient was advised to have a crown placed as soon as possible. The prognosis of tooth 37 was considered guarded, functional and favorable upon review.

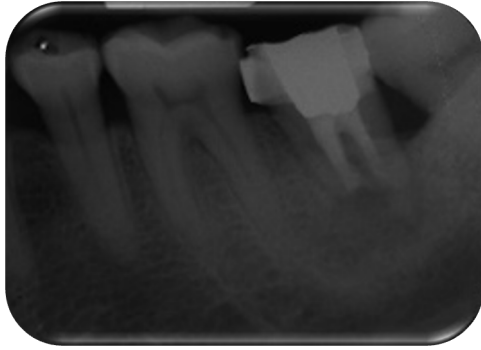

Fig. 7 Post-operative

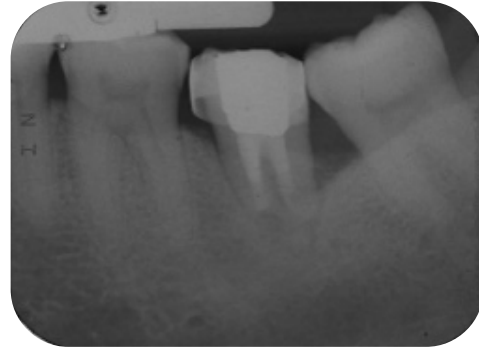


Fig. 8 7-months review

DISCUSSIONS

Based on the severity of the resorptive process, different treatment option has been proposed; non-surgical root canal retreatment with thermoplasticized injectable gutta percha without membrane barrier and extraction. For this case, ‘membrane barrier technique’ was advised due to the size of the resorption and probability of extrusion. This method has been advised as it has the capability of controlled placement of MTA to a desired level. A few cases reported that MTA may be inserted at the apical region of the root to form an artificial barrier in the apex due to the wide nature of apical foramen (Araújo *et al.*,2010,Pace *et al.*,2008). MTA has been proposed and tested as an alternative procedure to prevents overextension of filling material and ensuring good apical seal (Bates *et al.*,1996; Torabinajed *et al.*,1997). Araújo *et al.*, (2010) had decided on the usage of calcium sulphate matrix as a protection to prevent extravasation of MTA. Bargholz (2005) presented a modified matrix concept for the repair of root perforations using MTA. His concept was using a resorbable collagen that reconstructs the outer shape of the root and facilitates the adaptation of MTA (Bargholz,2005). The membrane matrix was placed subsequently by MTA in this case to avoid overextension. Many studies have shown that MTA exhibit good biocompatibility (Keiser *et al.*,2005), providing good apical seal (Al-Kahtani *et al.*,2005) and stimulate bone reposition thus healing (Torabinahed *et al.*,1997).

For the application of MTA, no such pressure-resistant support is necessary. Small pieces of cut membrane matrix (Geitslich Bio-Gide[®], Geitslich Pharma AG, Bahnhofstrasse, Wollhusen, Switzerland) were used to place at the designated apex working length and keep it in place outside the root. A freshly mixed MTA has a soft consistency and may be applied without pressure; ultrasonic was used as an aid of placement. Direct observation of the wide apex through a dental operating microscope is extremely helpful. Al-Kahtani *et al.*, (2005) recommended the placement of a 5 mm apical barrier of MTA in cases of apexification, in allowing an excellent apical seal and prevented it from being displaced. His *in vivo* study achieved a relative success index of 81%. We followed his recommendation.

Despite a cautious prognosis, the radiographic evaluation at the seven-month follow-up revealed a reduction in the size of the periapical lesion and no progression of the exterior resorption associated with periodontal and periapical health tissues. The patient was ecstatic to maintain her tooth at the seven months review session. It is nevertheless preferable to acquire a longer review session to check the tooth's survival.

Over a standard radiography imaging, a follow-up with a **cone-beam computed tomography systems**. CBCT would be useful for greater definition and visibility of the lesion region⁴. Although the limitations of a conventional periapical radiograph in detecting periapical lesions may not support the regular use of CBCT in endodontic treatment, it may be used if additional information is needed for bone formation management.

CONCLUSION

Diagnosing and treating a root resorption case can be perplexing, so choosing the right management is risky. When the prognosis of the tooth is guarded upon consultation, thorough studies and discussion are essential for management. The functional tooth, resolving of periapical lesion and no signs and symptoms at the 7-months review provided a favorable outcome to once a guarded tooth.

REFERENCES

- Al-Kahtani A, Shostad S, Schifferle R, Bhambhani S (2005). In-Vitro Evaluation of Microleakage of an Orthograde Apical Plug of Mineral Trioxide Aggregate in Permanent Teeth with Simulated Immature Apices. **J Endod.** 31(2):117-119.
- Andreasen JO, Andreasen FM, Andersson L (2018). *Textbook and Color Atlas of Traumatic Injuries to the Teeth*. John Wiley & Son, West Sussex , UK...
- Araújo RA, Silveira CFM, Cunha RS, De Martin AS, Fontana CE, Bueno CES (2010). Single-session use of mineral trioxide aggregate as an apical barrier in a case of external root resorption. **J Oral Sci.** 52(2):325-328.
- Bargholz C (2005). Perforation repair with mineral trioxide aggregate: a modified matrix concept. **Int Endod J.** 38(1):59-69.
- Bates CF, Carnes DL, Carlos E (1996). Longitudinal sealing ability of mineral trioxide aggregate as a root-end filling material. **J Endod.** 22(11):575-578.
- Berman LH, Hargreaves KM(2015). *Cohen's Pathways of the Pulp Expert Consult*. Elsevier Health Sciences, St Louis, Missouri.
- Gartner AH, Mack T, Somerlott RG, Walsh LC (1976). Differential diagnosis of internal and external root resorption. **J Endod.** 2(11):329-334.
- Goerig AC, Michelich RJ, Schultz HH (1982). Instrumentation of root canals in molar using the step-down technique. **J Endod.**8(12):550-554.
- Keiser K, Johnson CC, Tipton DA (2000). Cytotoxicity of mineral trioxide aggregate using human periodontal ligament fibroblasts. **J Endod.**;26(5):288-291.
- Pace R, Giuliani V, Pagavino G (2008). Mineral trioxide aggregate in the treatment of external invasive resorption: a case report. **Int Endod J.** 41(3):258-266.
- Torabinejad M, Ford TRP, McKendry DJ, Abedi HR, Miller DA, Kariyawasam SP (1997). Histologic assessment of mineral trioxide aggregate as a root-end filling in monkeys. **J Endod.** 23(4):225-228.

