

Iatrogenic Lingual Neuralgia Following Laryngoscopy

Aziah Ab Rani, Sanjeevan Nadarajah

Department of ORL-Head & Neck Surgery, School of Medical Sciences, Universiti Sains Malaysia, Kota Bharu, Kelantan, Malaysia

Received

19th March 2018

Received in revised form

25th June 2018

Accepted

23rd July 2018

Corresponding author:

Dr. Aziah Ab Rani

Department of ORL-Head & Neck
Surgery,
School of Medical Sciences
Universiti Sains Malaysia,
Kubang Kerian Campus,
Kota Bharu, Kelantan,
Malaysia.
Email: maestro_azy@yahoo.com

ABSTRACT

Tongue pain attributed to lingual neuralgia has been reported following dental and oral surgical procedures. Lingual nerve insult through traction and compression during laryngoscopic examination has been proposed as possible etiology for lingual nerve neuralgia. We report a case of tongue ischemia during laryngoscopic procedure which resulted in lingual neuralgia. We recommend that intermittent release of pressure by relaxing the instrument or gag and monitoring the perfusion state of the tongue will reduce the risk of this lingual neuralgia.

KEYWORDS: Lingual neuralgia, Laryngoscopy, Tongue ischaemia

INTRODUCTION

Lingual neuralgia is a known complication following dental procedures, especially following dental block injections and extraction of the lower third molars [1, 2]. However, its incidence following a laryngoscopy procedure is rarely documented.

CASE PRESENTATION

A 40 year old lady who was on tracheostomy for 3 months was admitted to our center following a finding of an intraluminal granulation tissue during tracheostomy change. A flexible scope revealed that the granulation tissue was at the suprastomal region, and subsequently she was booked for a direct laryngoscopy and suspension laryngeal microsurgery to remove the granulation tissue. Intra-operatively, we noted a bluish discoloration of the tongue following

insertion of a direct laryngoscope resting on the patient's tongue stabilized with a suspension for appropriate visualization of the larynx (Figure 1). The procedure took thirty minutes to complete.

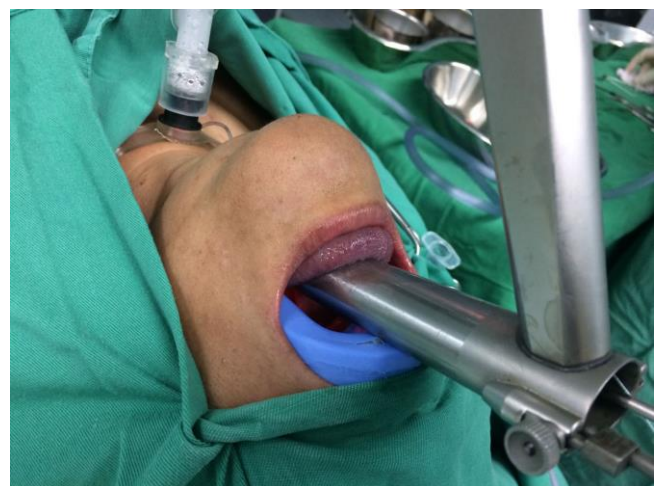


Figure 1 Bluish discoloration of tongue suggestive of ischaemia due to lingual artery compression by the laryngoscope held by suspension

Post-operatively, the patient was quite well and managed to be weaned off her tracheostomy tube. However, at two weeks post-op, she complained of pain which was localized at the root of the tongue, associated with on and off numbness and tingling sensation which radiated to the tip of the tongue. There was however no loss of taste sensation to the anterior two-thirds of the tongue, and she did not have any problems on speech articulation.

DISCUSSION

Direct laryngoscopy or suspension laryngoscopy is a common procedure used for both diagnostic and therapeutic purposes in laryngology. A laryngoscope is a hollow, rigid tool which allows the surgeon to fully visualize the pharynx and larynx with the aid of illumination from a fiber optic light. Often, the distal tip of the laryngoscope blade is placed at the base of tongue and its handle may be attached to a suspension device which involves a supporting arm that lies on a base placed on the patient's anterior chest. This allows the surgeon to free both hands to use other instruments to perform further procedures involving the larynx.

The two main mechanisms reported to have caused lingual neuralgia are compression and transection of the nerve [3]. In our patient, excessively tight compression of the blade against the base of tongue during laryngoscopy may have resulted in decreased perfusion of the lingual artery which in turn caused lingual ischaemia and neuropathy.

The lingual nerve is a branch of the posterior division of the mandibular nerve, which is a branch of the trigeminal nerve. It also carries the chorda tympani, a branch of the facial nerve which carries taste sensation to the anterior two-thirds of the tongue. Injuries to the lingual nerve may result in numbness, hypoesthesia of the tongue's mucous glands and loss of sensation to the anterior two-thirds of the tongue. It may concurrently cause anaesthesia of the lingual gums and speech articulation disorders [3]. Our patient however had no loss of sensation to the anterior two-thirds of the tongue and no speech articulation problems.

A diagnosis of lingual neuralgia is made through significant history of recent laryngoscopy procedure and symptoms described for the patient.

Cox et al suggested the use of magnetic resonance neurography to aid in the diagnosis of peripheral trigeminal nerve injury. This may be considered if the patient has suspected transection of the lingual nerve [4]. During laryngoscopy the nerve is unlikely to be transected, and may have instead developed a neuropraxic injury due to pressure from the laryngoscope which resulted in stretching of the nerve [5].

A study performed by Tassema B et al involving one hundred patients who underwent microlaryngoscopy discovered that altered sensation and taste post-operatively was more common in females, with symptoms decreasing over the time of three months. In addition, patients who underwent laryngoscopy for more than one hour duration were four times more likely to develop tongue symptoms compared to those whose operative time was less than thirty minutes [6]. Our patient in this case is also a female, and developed complete spontaneous resolution of the lingual neuralgia at three months post-operatively.

Surface capillaroscopy of the ventral tongue mucosa during suspension microlaryngoscopy procedures in a study performed by Bryson observed venous stasis, capillary congestion and almost absent blood flow within 10 minutes post-suspension. Upon releasing the suspension, the return of the capillary flow was proven to be sluggish compared to the pre-suspension blood flow [7]. This supports our recommendation for intermittent relaxation of the perfusion or gag in order to prevent ischaemic injury to the lingual artery.

CONCLUSION

A surgeon performing direct laryngoscopy with the aid of suspension should be mindful of the consequence of excessive compression of the tongue. The tongue should always be examined to ensure that it is pink, suggestive of adequate perfusion and the suspension laryngoscope should be adjusted intermittently to facilitate adequate blood flow. Patients should also be routinely informed of the possible complication of lingual neuralgia following any procedure involving direct laryngoscopy. Adequate measures involving monitoring the perfusion of the tongue while

intermittently releasing the suspension to alleviate the compression caused by the laryngoscope should be taken in order to prevent this complication from occurring.

Conflict of Interest

Authors declare none

REFERENCES

1. Robinson PP, Smith KG. Lingual nerve damage during lower third molar removal: a comparison of two surgical methods. *Br Dent J.* 1996; 180(12): 456-61.
2. Bataineh AB. *J Oral Maxillofac Surg.* Sensory nerve impairment following mandibular third molar surgery. 2001; 59(9): 1012-7.
3. Piagkou M, Demesticha T, Piagkos G, Georgios A, Panagiotis S. Lingual nerve entrapment in muscular and osseous structures. *Int J Oral Sci.* 2010; 2(4): 181-9.
4. Cox B, Zuniga JR, Panchal N, Cheng J, Chhabra A. Magnetic resonance neurography in the management of peripheral trigeminal neuropathy: experience in a tertiary care centre. *Eur Radiol.* 2016; 26(10): 3392-400.
5. Gaut A, Williams M. Lingual nerve injury during suspension microlaryngoscopy. *Arch Otolaryngol Head Neck Surg.* 2000; 126(5): 669-71.
6. Tessema B, Sulica L, Yu GP, Sessions RB. Tongue paresthesia and dysgeusia following operative microlaryngoscopy. *Ann Otol Rhinol Laryngol.* 2006; 115(1): 18-22.
7. Bryson PC, Surface Capillaroscopy can be Used to Monitor Tongue Perfusion During Suspension Microlaryngoscopy. 2016. Available from <https://consultqd.clevelandclinic.org/2016/03/surface-capillaroscopy-can-used-monitor-tongue-perfusion-suspension-microlaryngoscopy/>