

Paediatric Transoral Robotic-Assisted Adenotonsillectomy: A New Anaesthetic Experience in Malaysia.

Zawiah Kassim, Fauziah Ahmad, Rusnaini Mustapha Kamar, Karis Misiran

Department of Anaesthesiology & Intensive Care, Faculty of Medicine, UiTM, Selangor, Malaysia

Received

2nd April 2019

Received in revised form

21st August 2019

Accepted

26th September 2019

Corresponding author:

Dr. Zawiah Kassim,

Department of Anaesthesiology &
Intensive Care,

Faculty of Medicine,

UiTM Medical Centre,

Sungai Buloh Campus, Jalan Hospital,

47000 Selangor,

Malaysia.

Email: zawiah81@uitm.edu.my

ABSTRACT

Safety and feasibility of transoral robotic surgery (TORS) in adults for otolaryngology surgery, mainly in the treatment of oropharyngeal carcinoma and obstructive sleep apnoea has already been established several years ago. However, less is known with respect to the role and safety of TORS for otolaryngology surgery in the paediatric age group and its description in the literature is currently insufficient. As paediatric patients are unique in their anatomy, physiology and pharmacological kinetic, special attention and consideration has to be applied when using TORS, hence this increases the perioperative challenges. Herewith we present our experience in anaesthetising a paediatric patient for TORS adenotonsillectomy which is the first not only in our centre but in Malaysia. Our major obstacle was the limited airway access as the area of concern was shared by the anaesthesiologist, surgeon and also the robotic system. Haemodynamic stabilisation was a challenge compared to the conventional method as the operative time increased due to robot docking time and the new surgical learning process. In our opinion, the key point for the success of TORS adenotonsillectomy in paediatric patients is good communication and teamwork between all personnel involved in the surgery.

KEYWORDS: Transoral robotic surgery, paediatric patients, adenotonsillectomy, tonsillectomy, adenoidectomy.

INTRODUCTION

Minimally invasive surgery with lesser morbidity and greater post-operative advantages has been the driving force behind the application and advance of robotic surgery. Since the safety and feasibility of transoral placement of the robotic endoscope and instruments described by Hockstein et al in 2006, its role in head and neck surgery has been rapidly expanding [1]. TORS has been shown to be technically feasible, safe and effective for the diagnosis and treatment of a wide spectrum of adult otorhinolaryngology diseases from benign to malignant. However, experiences of TORS for management of paediatric otorhinolaryngology diseases is still lacking. Rahbar et al first described TORS as a feasible option for paediatric airway surgery in 2007, but due to the size of the robotic surgical instrument, limited transoral access was encountered in few cases [2]. With innovation of robotic technology, miniaturisation of instruments have dramatically

increased the scope of surgery in paediatric age group including tonsillectomy. We present our first experience in a paediatric patient who underwent adenotonsillectomy using the Da Vinci® telerobotic system (Intuitive Surgical Inc. USA) in our centre.

CASE PRESENTATION

An 8-year old girl presented to the otorhinolaryngology clinic with recurrent tonsillitis. She had underlying intermittent asthma on metered dose inhaler (MDI) Salbutamol as needed (p.r.n). On examination, she was found to have enlarged bilateral tonsils (Grade 4) with hypertrophy of the inferior turbinate. Her airway evaluation using modified Mallampati score revealed a complete visualisation of the soft palate (score of 1) which predicted easy intubation with direct laryngoscopy. Other physical examinations were essentially normal. Although she was small for her age weighing 18kg, she had a good mouth opening as her



maximal inter-incisal distance was able to accommodate vertically align 3 fingers (index, middle and ring fingers). Preoperative blood investigations were within normal limits. She was scheduled for TORS tonsillectomy, adenoidectomy and turbinoplasty for recurrent tonsillitis with turbinate hypertrophy. No oral premedication was given to this patient.

In the operating theatre, standard intraoperative monitoring consisting of pulse oximetry, non-invasive blood pressure, electrocardiogram and capnography (end-tidal CO₂) were applied prior to induction. Anaesthesia was induced by facemask according to conventional incremental technique (2, 4, 6, 8 % sevoflurane every 5 breaths) in 100 % oxygen with patient lying on the operating table. The anaesthesia workstation was placed to the left of the patient (Figure 1). As soon as the depth of anaesthesia was deemed appropriate, an intravenous cannula size 22G was inserted over dorsum of right hand, which was then followed by administration of intravenous fentanyl 1.5 µg/kg and intravenous rocuronium 0.6 mg/kg. As we

anticipated that the patient's arm would be difficult to access intraoperatively once the robot had been docked, intravenous access was secured and connected to line tubing with extension. Direct laryngoscopy showed a Cormack-Lehane of 1 and a 5.5 mm cuffed RAE endotracheal tube (ETT) was successfully placed in a single attempt. The ETT was anchored centrally at 16.5 cm after confirmation with capnography tracing and an equal breath sound bilaterally on chest auscultation. The ETT was secured by taping it at the midline of the lower lip and padding was applied between the tube and patient chin for better tube fixation and prevention of pressure damage. As airway access would be extremely restricted once the robotic arm has been positioned to the patient, the tube has to be meticulously secured to prevent any accidental dislodgement that could be disastrous (Figure 2). A throat pack was then put in place. Both eyes were protected with padding and taped since there was a potential for the robotic arm to get in contact with the patient's eyes.

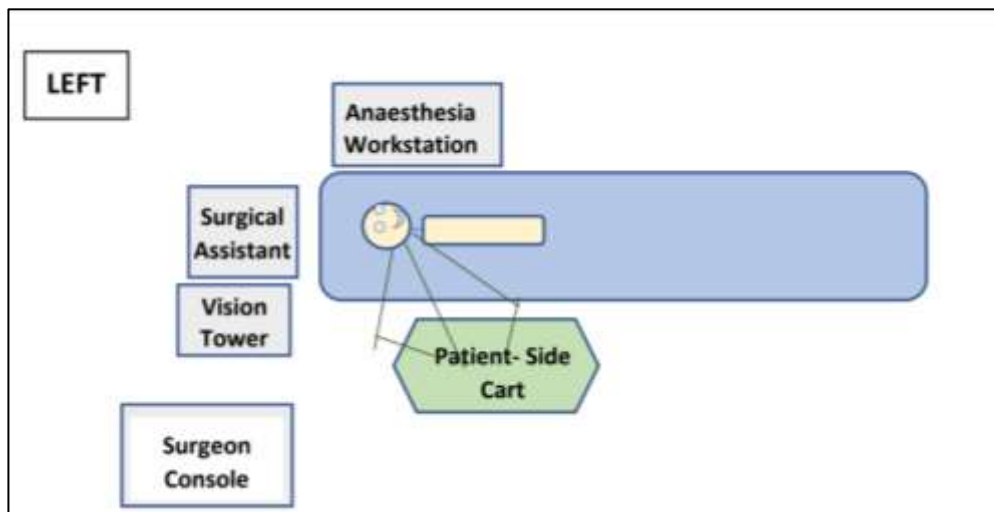


Figure 1 Operating room set up for TORS adenotonsillectomy

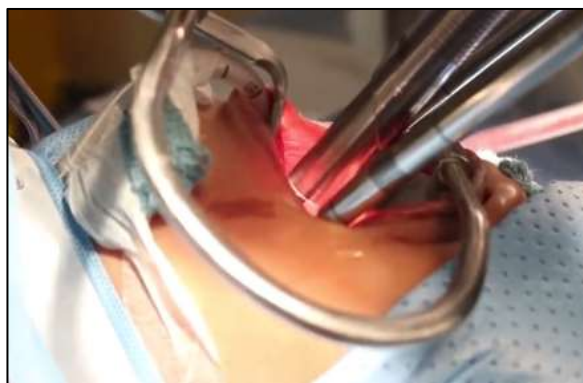

Figure 2 Close-up view of the positioning of ETT with robotic arms in place

Rectal temperature probe was then inserted for continuous intraoperative core temperature monitoring as paediatric patients is a known group with higher risk to develop perioperative hypothermia. Furthermore, we anticipated a prolonged surgery as this was a new surgical technique for us. Aside from the usual intraoperative warming device consisting of underbody blanket and force air warmer to maintain normothermia, all limbs were bandaged. Heat and moisture exchanger (HME) was also connected to patient's breathing circuit to humidify gases used for ventilation.

Patient was then placed in supine position with both arms at the sides. A shoulder roll was placed underneath the patient's shoulder to extend the neck as to improve surgical visualisation. The operating surgeon then placed a retractor in the patient's mouth to gain optimum surgical exposure. The surgical assistant worked from the patient's head and the robotic arms positioned at the patient's right (Figure 1). Three robotic arms were employed: one to handle a 12 mm stereoscopic endoscope at an angle of 0° or 30° and the other two equipped with 5 mm EndoWrist instruments (Intuitive Surgical Inc.). Once the robot was docked into the final position (Figure 3), movement of the patient was avoided by maintaining adequate depth of anaesthesia and muscle relaxation.

Throughout surgery, anaesthesia was maintained with fresh gas flow of 1 L/min (50% oxygen-air), sevoflurane (by achieving MAC between 1.0 - 1.3%) and intravenous morphine 2 mg for analgesia and suppository paracetamol 625 mg as part of multimodal analgesia. An intermittent bolus of rocuronium 5 mg was administered every one hour for muscle relaxation to allow optimal surgical exposure and to prevent coughing since this might cause tearing

of the tissue by the robot. Intravenous dexamethasone 4 mg was also given prior to incision for prevention of airway oedema as well as to provide analgesia postoperatively. Ventilatory parameters were adjusted to maintain an end-tidal CO₂ between 35 – 40 mmHg.

Intraoperative fluid maintenance was given as per 4/2/1 rule. Thus, this 18 kg patient received hourly fluid maintenance of 56 ml per hour of 0.9 % sodium chloride solution with additional fluid replacement to correct her deficit from preoperative fasting and ongoing third space loss as per surgical procedure protocol.

Our first TORS adenotonsillectomy was successfully completed after 2 hours 45 minutes including 1 hour 30 minutes for preparation of robotic equipment till docking (Figure 4). Meticulous haemostasis was confirmed before removing the robotic arm and retractor from the patient. Surgery was then followed by turbinoplasty using the conventional method after robot undocking. Total intraoperative blood loss was minimal. Patient was successfully extubated on table after reversing neuromuscular blockade. Amazingly, her immediate post-operative pain score was very good with a visual analogue scale of zero and no additional analgesia required in the recovery area. She was well with no observed post-operative nausea and vomiting or bleeding from surgical site. After half an hour monitoring in the recovery area, she was transferred to the ward for continuation of care. Regular syrup paracetamol 270 mg every 6 hour was continued in the ward as a post-operative analgesia. Patient was discharged home the following day. She was seen in the clinic two weeks later and was well.

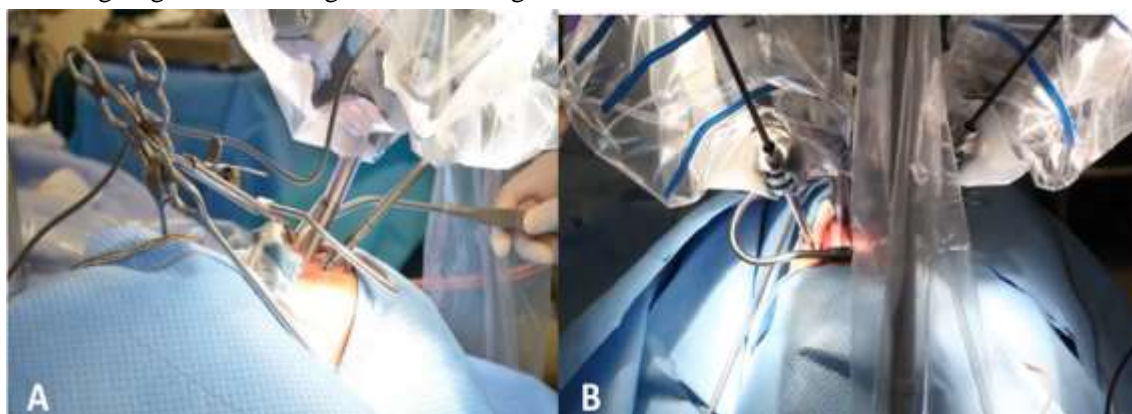


Figure 3 Docking of robotic apparatus. A: View from anaesthesiologist's side (patient left side), B: View from upper side of patient

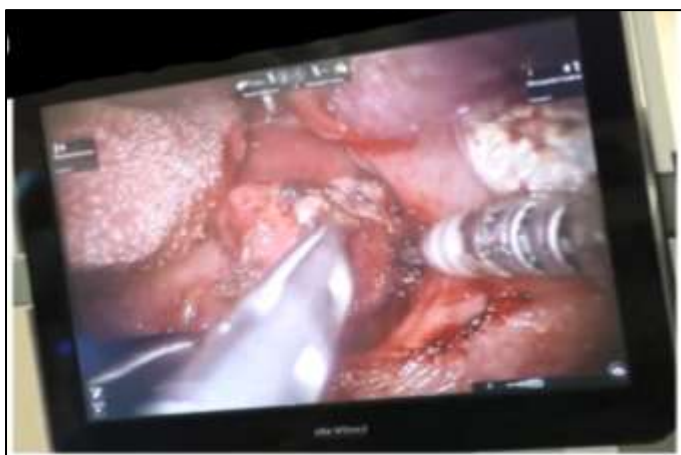

Figure 4 Three-dimensional endoscopic view with magnification of key structures produced by TORS. The clean dissection plane of tonsillectomy can be seen.

DISCUSSION

A surgical procedure performed through the oral cavity using at least three robotic arms which allows bimanual manipulation of tissues is known as TORS [3]. Application of this robotic technology in paediatric patients who are known to have narrow surgical working space, has greatly improved the quality of surgical visualisation, exposure and dissection. A complete excision with precise incision and greater protection of surrounding structures can be achieved with this method hence offer a faster recovery with less postoperative pain and shorter hospital stay [2]. Leonardis et al in his study involving 16 paediatric patients who had undergone TORS lingual tonsillectomy, has reported few postoperative complications in his patients which include bleeding from surgical site, pneumonia, fever of unknown aetiology and poor pain control [4]. The possible factors that may attribute to these postoperative outcomes were patients underlying comorbidities, indication for surgery and selection of perioperative multimodal analgesia. In our case, excellent pain control was observed despite minimal opioid usage intraoperatively and no postoperative complication was noted on follow up visit.

In 2007, Rahbar et al used five living patients with laryngeal cleft to assess precision and tissue handling of transoral approach of robotic system [2]. In 3 out of 5 patients, limited transoral access had caused failure of TORS for repair of laryngeal cleft. Equipment size was the main limiting factor for these

procedures which resulted in limited surgical access in these patients [2]. Since then, advances in robotic technology had introduced a smaller robotic instrument which ideally suited paediatric populations. Leonardis et al again reported successful completion of TORS in all of his patients using a 5 mm instruments of the Da Vinci surgical robot [4]. This successful completion of surgery may be contributed by the downsized robotic instrument to 5 mm as compared to 12 mm and 8 mm as reported by Rahbar et al [2]. A review of TORS for paediatric laryngotracheal reconstruction by Faust et al in 2008 further support this finding [5]. He suggested if at least 2 robotic instruments can be placed intraorally, the feasibility of TORS will be improved thus further expand the scope of robotic surgeries in paediatric patients [5].

The primary hurdle faced in this case was to obtain a safe and adequate means to administer anaesthesia, as we as the anaesthesiologists share the same place of interest with the surgeons. Due to this anatomical constraint, arrangement of robotic system for TORS adenotonsillectomy is unique compared to other robotic surgeries. In order to facilitate surgery, our theatre setting was adjusted as Figure 1. To allow docking of the bulky robotic arm as close as possible to the patient's head, the anaesthesia workstation was positioned to the left of the patient. This arrangement required an anaesthetic breathing circuits to be longer to reach the patient. Anaesthetic breathing circuit is part of conducting zones that does not take part in gas exchange [6]. Therefore, increments in the length of breathing circuit will increase the dead space and subsequently reduce alveolar ventilation which could be detrimental to a paediatric patient who has a smaller lung and lower tidal volume compared to an adult [6]. In our centre, time-based capnography is routinely used for monitoring dead space intraoperatively, despite the fact that volumetric capnography is known to be more accurate method to evaluate dead space. Monitoring alveolar dead space using volumetric capnograph requires other specialised equipment which is not available in our centre. Since this patient had a well-controlled asthma with no significant hypoxaemia and no other cardiac output-related dead-space changes disorder, time-based capnograph is a useful dead space monitoring as it is highly correlated with volume base

capnograph in a healthy mechanically ventilated patient [6]. As the length of breathing circuit increases, the length of capnograph sampling tubing must also increase and this will lead to a slower capnograph response time. Hence, special consideration must be given intraoperatively to the capnograph waveform tracing as the increase in transit time and rise time from a longer sampling tubing will result in delayed appearance of capnograph waveform at the detector as well as abnormal waveform tracing. Underestimation of EtCO₂ reading due to dispersion of gases along the longer tubing is also anticipated [6].

Since intraoral space is premium in paediatric airway cases, present of ETT may impede access to key structures. It has been found that in order not to hinder the ability of instruments used to attain maximal freedom of movement, the placement of nasal or oral ETT of the appropriate size of the patient is crucial [4]. In our case, we used cuffed pre-formed oral RAE ETT instead of nasal RAE ETT as this patient was also planned for turbinoplasty, therefore avoiding the need of ETT exchange intraoperatively. This 'south-facing' tube has a pre-formed bend to reduce the risk of kinking and obstruction. It must be remembered that after docking the robot, access to the patient is limited and any change in patient position will not be possible. Therefore, all circuit connections especially ETT, monitors and vascular lines must be checked and secured properly at all time to ensure no disconnection that can lead to disastrous incident. In the event of emergency, quick de-docking of the robotic system is vital and this require practice and training among theatre staff in order to perform an emergency undocking effective and efficiently when the need arise.

As children has less insulating body fat compared to adult, this higher surface area to volume ratio contribute to proportionately higher heat loss [7]. This factor in combination with impaired thermoregulatory response along with reduced basal metabolic rate under anaesthesia further exposes this population to a higher risk for inadvertent hypothermia which was defined as a core temperature below 36 °C. In this case, we monitored core temperature through a rectal probe and we managed to maintain normothermia throughout surgery by the application of passive insulation as well as active skin warming device.

This first TORS adenotonsillectomy in our centre had shown excellent outcome with no complication experienced despite a lengthy procedural time. This patient had an excellent postoperative pain control which facilitated faster recovery and shorter hospital stay. We believe by performing more cases, the learning curve with respect to robotic setup and operative time will reduced remarkably as more experience will be gain by all the personnel involved in this procedure.

CONCLUSION

Our first experience anaesthetising a child undergoing TORS adenotonsillectomy was very exciting and challenging. Our main concerns were limited airway access as the surgical area was shared between anaesthesiologist, surgeon and the robotic system. A longer time was required with respect to robot docking time, surgical learning curve and anaesthetic familiarity. The key point of success for this new technique was a good communication and teamwork between all personnel involved in the surgery.

Conflict of Interest

Authors declare none

REFERENCES

1. Hockstein NG, O'Malley Jr BW, Weinstein GS. Assessment of intraoperative safety in transoral robotic surgery. *Laryngoscope*. 2006; 116(2):165-168.
2. Rahbar R, Ferrari LR, Borer JG, Peters CA. Robotic surgery in the paediatric airway: application and safety. *Arch Otolaryngol Head Neck Surg*. 2007; 133(1):46-50.
3. Weinstein GS, O'Malley Jr BW, Snyder W, Hockstein NG. Transoral robotic surgery: supraglottic partial laryngectomy. *Ann Otol Rhinol Laryngol*. 2007; 116(1):19-23.
4. Leonardis RL, Duvvuri U, Mehta D. Transoral robotic-assisted lingual tonsillectomy in the pediatric population. *JAMA Otolaryngol Head Neck Surg*. 2013; 139(10):1032- 1036.
5. Faust RA, Rahbar R. Robotic surgical technique for paediatric laryngotracheal

- reconstruction. *Otolaryng Clin N Am.* 2008; 41(5):1045-1051.
6. Bhalla AK, Rubin S, Newth CJ, Ross P, Morzov R, Soto-Campos G, Khemani R. Monitoring dead space in mechanically ventilated children: volumetric capnography versus time-based capnography. *Respir Care.* 2015; 60(11):1548-1555.
 7. Bajwa SJ. Perioperative hypothermia in paediatric patients: diagnosis, prevention and management. *APICare.* 2014; 18(1): 97-100.